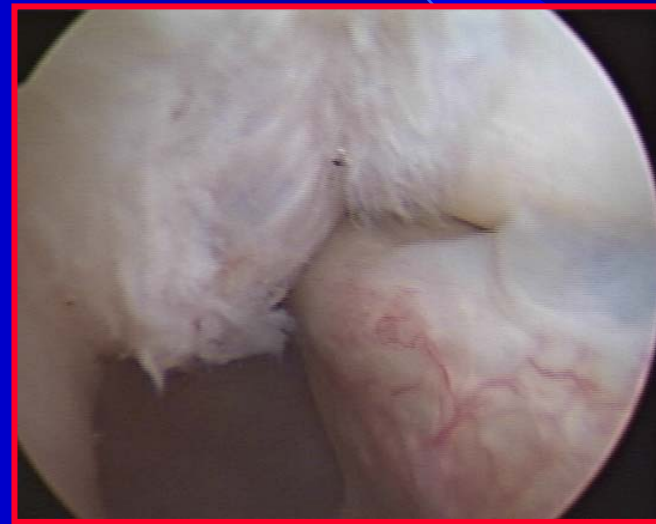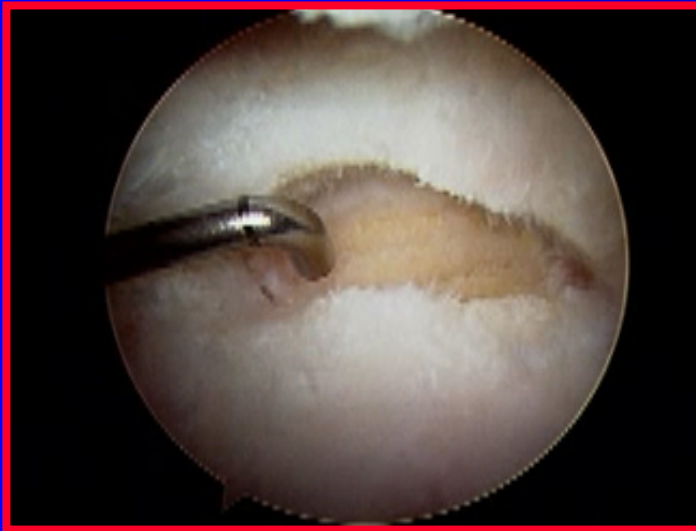


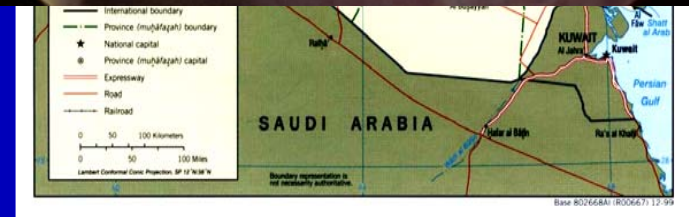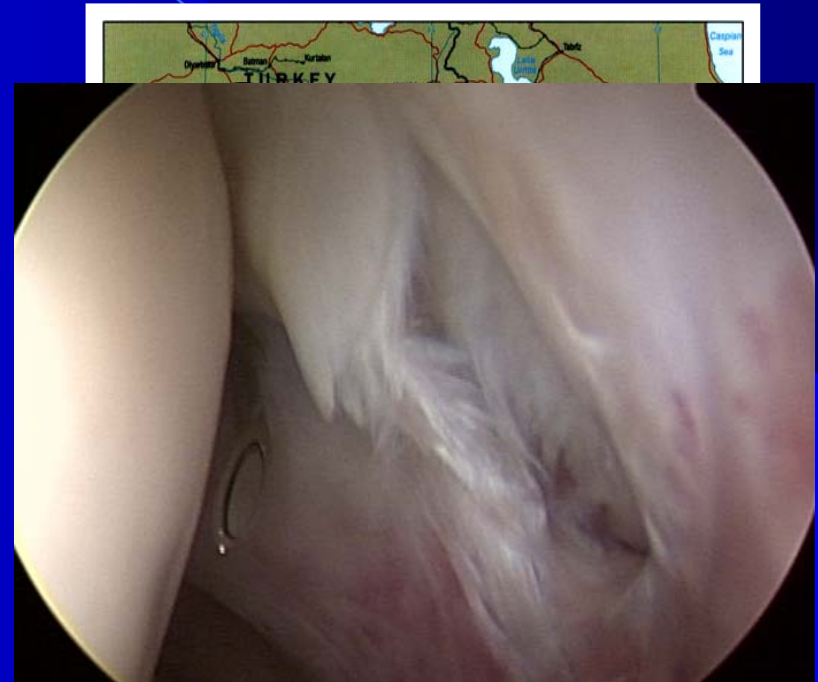
# Partial Tears of the Rotator Cuff: What to do ?



Jeffrey L. Halbrecht, MD  
San Francisco, CA

# The Current Situation...

- We know it's a problem
- We don't have a good solution
- Everyone has an opinion
- We know we can make the problem worse....
- But- can we make it better ?

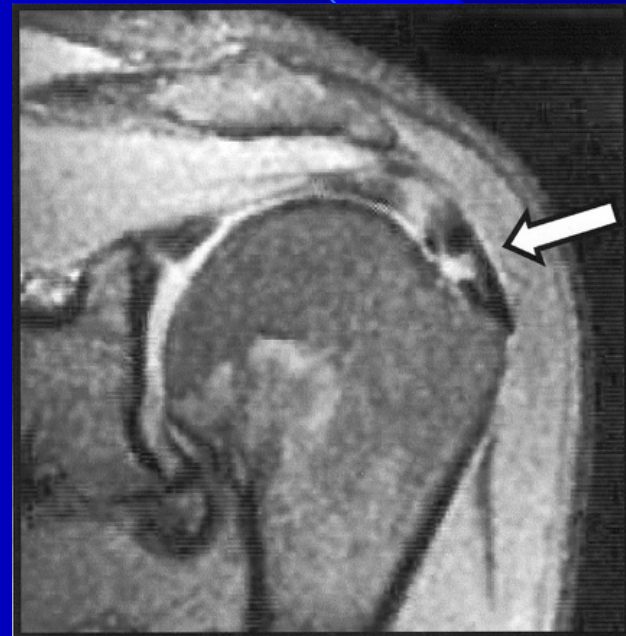

# What do we really know ?



# Definition:

- What is a partial RTC tear ?
  - Types
    - Bursal
    - Undersurface
    - Intrasubstance



# Classification

- Ellman

- Grade I

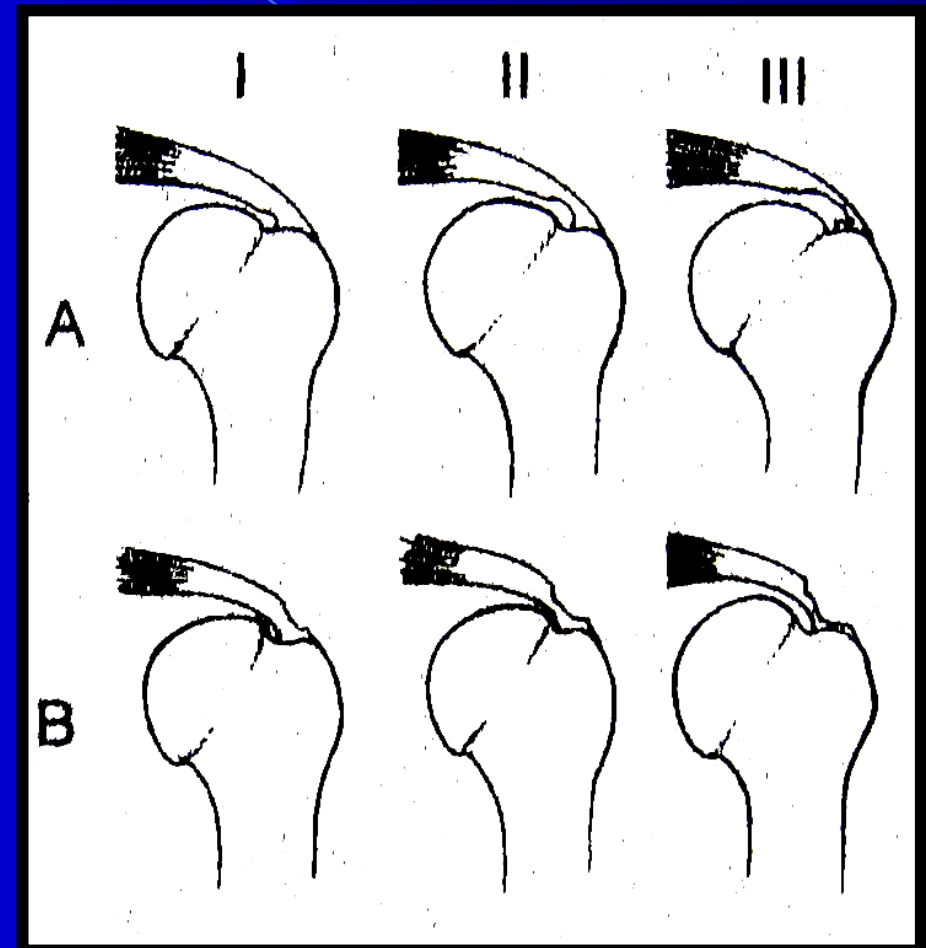
- < 25% (< 3mm)

- Grade II

- 25-50% (3-6 mm)

- Grade III

- >50% (>6mm)

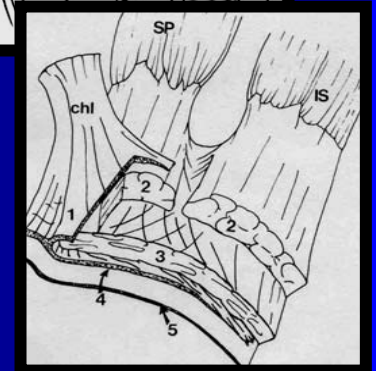
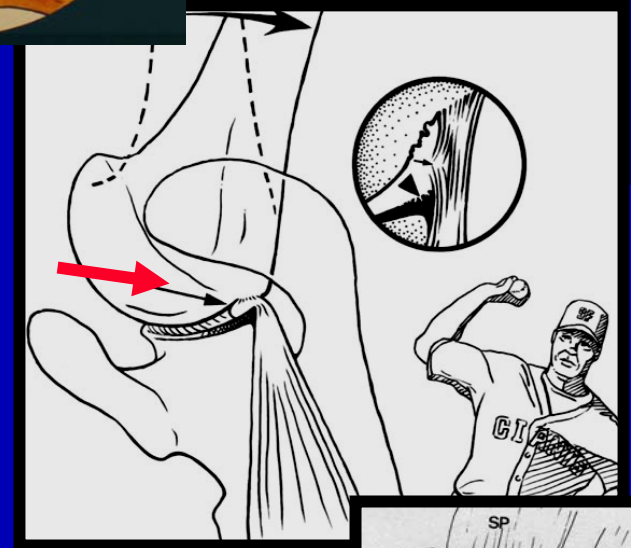
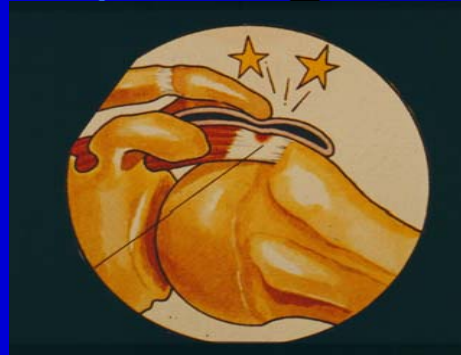

# Incidence:

- Cadaver Studies:
  - Fukuda 1990:
    - 249 cadaver dissections:
    - 7% complete
    - 13% partial
  - Uthoff:
    - 306 dissections
    - 19.9% complete tears
    - 32 % partial
- Clinical studies: articular vs. bursal
  - Cordasco: 82%
  - Webber: 88%

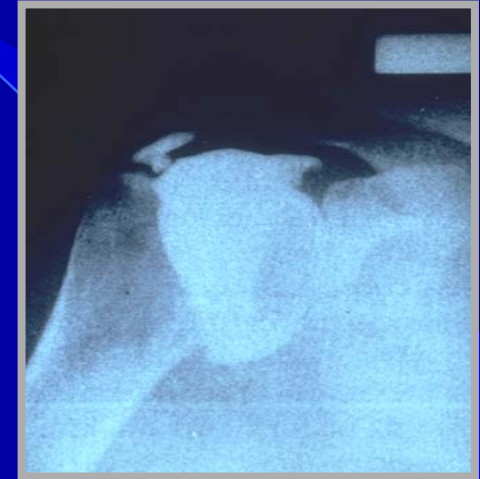
# PTRCT: Pathogenesis

- Bursal:
  - outlet impingement
- Articular:
  - Internal impingement:
    - repetitive normal contact
    - tight post capsule (Morgan)
    - lax anterior capsule (Jobe)
- Intrasubstance:
  - Traction (tensile overload)
  - Degenerative
  - Vascularity



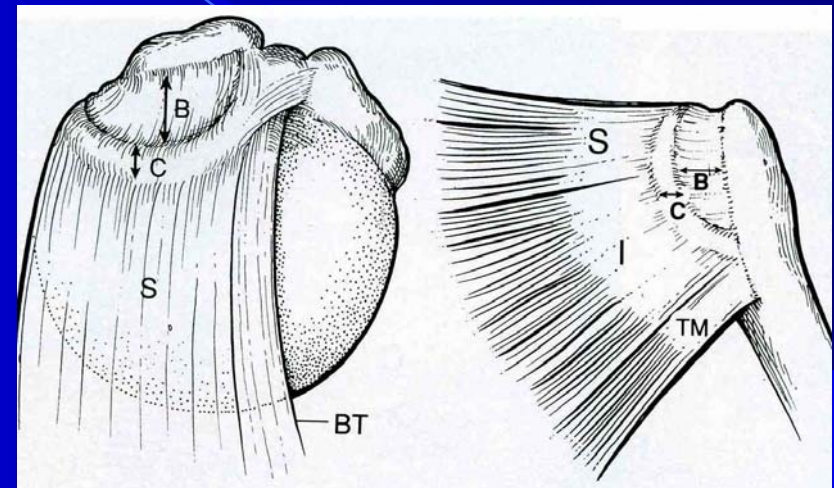
# PTRTC tears: Natural History

- Yamanaka 1994- Conserv RX
  - Serial arthrography: (40 pts. articular)
    - 52% enlarged
    - 28% full thickness tears
    - 10 % smaller
    - 10% 'healed'
- Coradasco 2002- ASD Debride
  - grade I-II: no progression at 10 years
- Weber 1999: - ASD Debride
  - grade III: 3/32 progressed to full 2-7 years.  
NO healing observed at second look



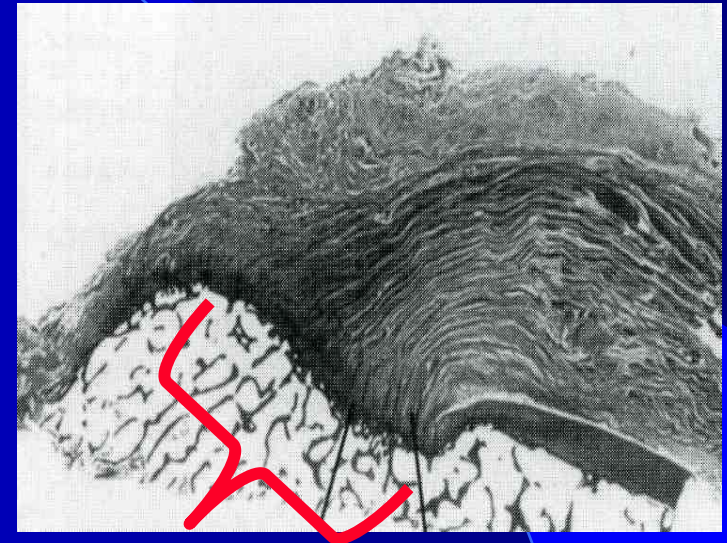
# Anatomy of the RTC

- Rotator Cable:
  - thickening of cuff (biceps to TM)
- Rotator Crescent:
  - thinner cuff tissue medial to cable (poor blood supply)
- Bursal side:
  - Thicker collagen bundles
  - Parallel orientation
  - Greater tensile strength
- Articular side:
  - Thinner
  - More random orientation
  - 50% less tensile strength



# Anatomy: Supraspinatus Footprint

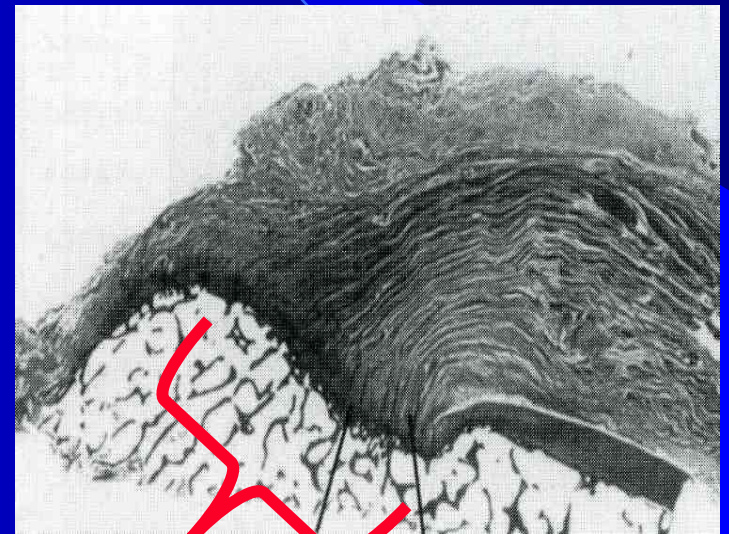
- Warren: *AOSSM 2004*
  - 12.7-16.3 mm
- Curtis *AANA 2002*
  - 16mm (12-22)
- Nottage *Arthroscopy 2004:*
  - Tendon thickness
    - 12.1mm at midtendon
    - 11.6 ant
    - 12.5 post



Footprint

# Footprint: Summary

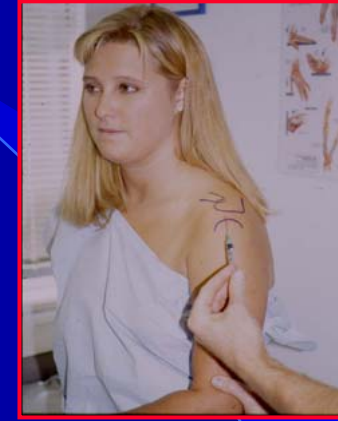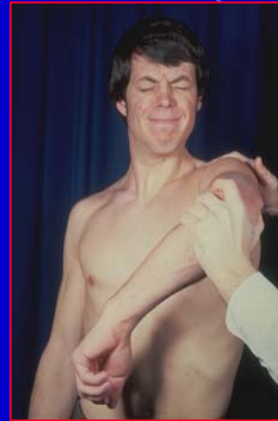- Approximately 12-16mm
- reasonable estimate:  
6-8 mm = 50%



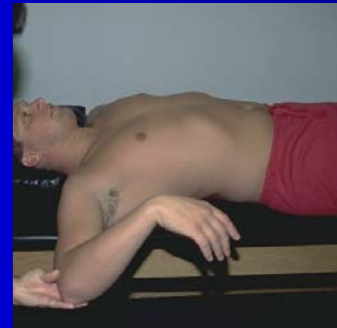12-16 mm

# Diagnosis: Physical Exam

- Bursal:
  - imp tests (Neer, Hawkins, SA inj)



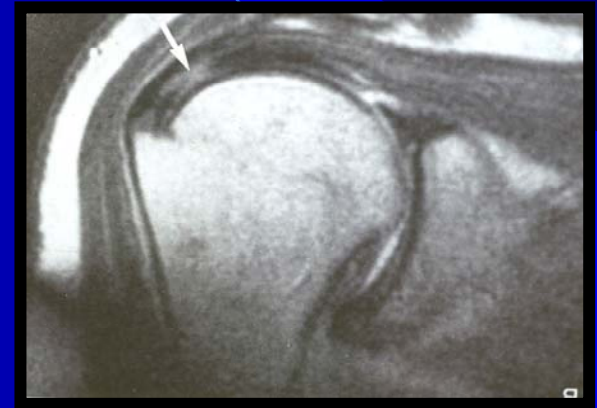- Articular:
  - int imp test, relocation test



- Intrasubstance: MRI diagnosis

# Diagnosis: Imaging

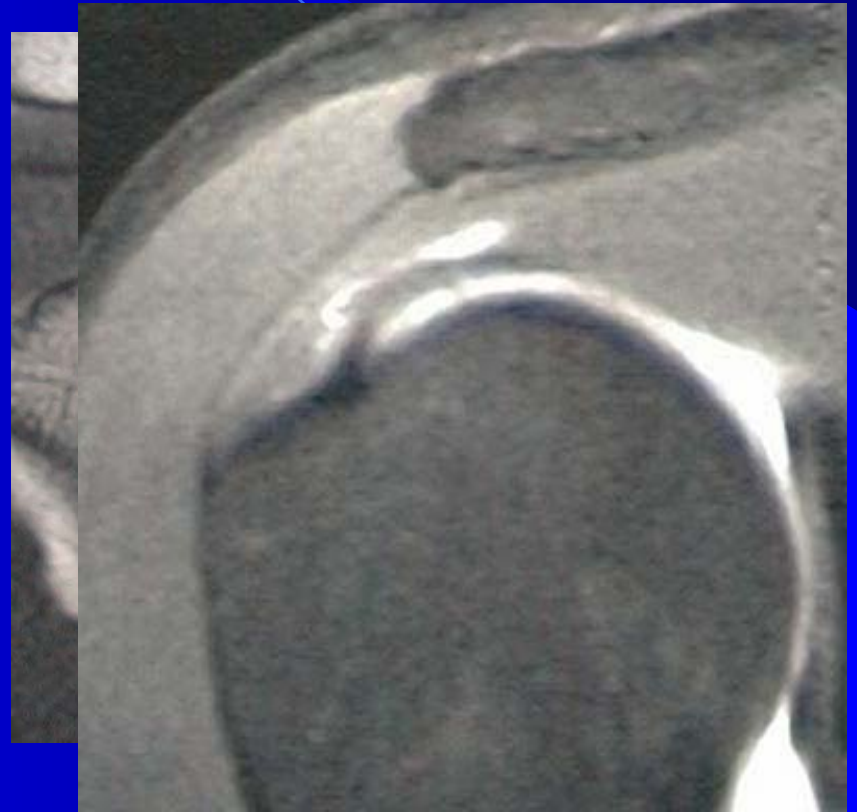
- Innacurate !!!
  - MRI:
    - Gartsman- 1995 83% false negative
  - MRI Arthrog:
    - Hodler 1992: 40% false neg
  - U/S:
    - Traugher 56% sensitive



# Diagnosis: MRI Examples

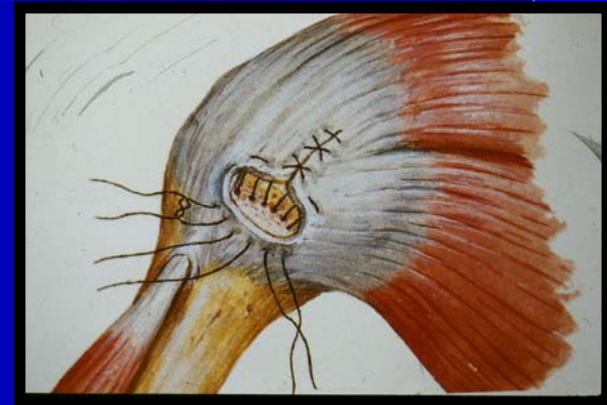
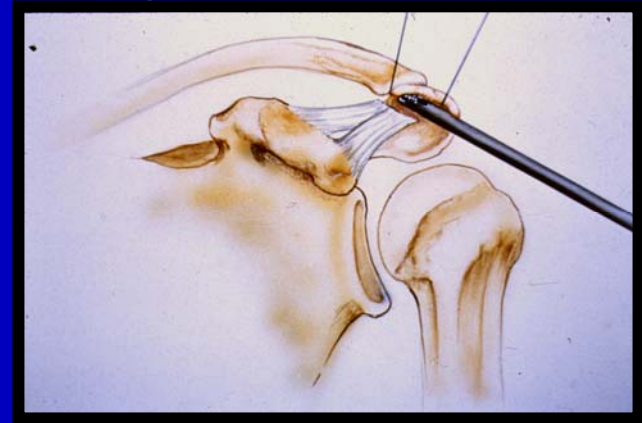
---

- MRI – cuff degen.,  
bursal fluid
- MRA – filling defect;
- MRA- ABER view
- MRA -Intrasubstance



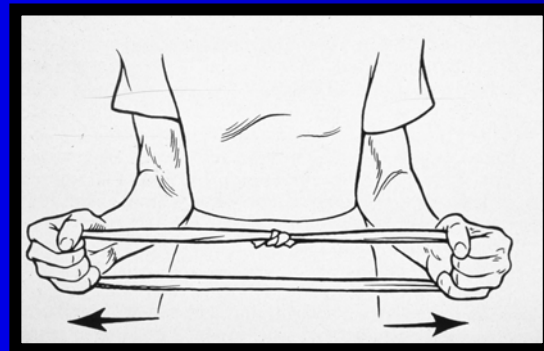
# What are available treatment Options ?

- Non- surgical
- Debride
- Debride + ASD
- Repair in situ
- Complete and repair



# Non surgical Management

- Try First !!
  - MRI may be wrong !
  - 40% success ( Breazeale, and Craig- 1997 OCNA)
  - McConville , Ianotti 1999 JAAOS
  - Morrison: Burkhead (ed) 1997

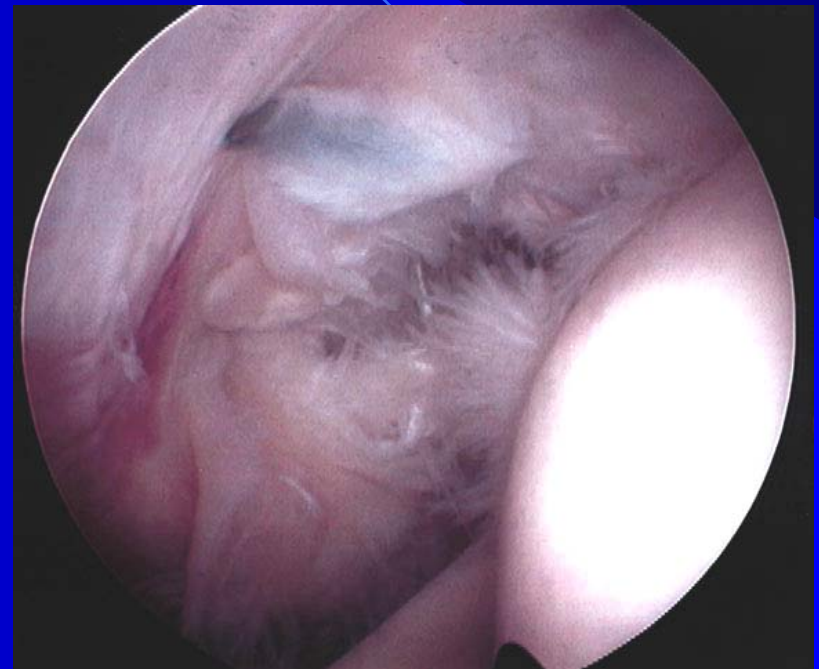

# Non Surgical Management

- Bursal side tears:
  - NSAID
  - RTC strengthening
  - Cortisone inj
- Articular side tears:
  - Treat tight posterior capsule (stretching)
  - Stabilization exercises

# Surgical Management:

- What do we know ?
- Review of the literature.....



# Surgical Results: Debridement Alone

|                      |                                    |
|----------------------|------------------------------------|
| Andrews 1985:        | 85%                                |
| Oglivie-Harris 1986: | 50%                                |
| Snyder 1991:         | 84% no corr to size/no progression |
| Budoff 1998:         | 87% satisfied, 85% G/E by UCLA     |

# Surgical Results: Debridement + ASD

## ● Short Term

- Ryu 1991: 84% satisfactory (debrid=ASD)
- Gartsman 1990 82.5% sig improved
- Olsewski 1994 81% satisfactory
- Esch 1988 82% satisfied (1 year)

## ● Longer Term

- Weber 1997 Grade III (2-7 yrs)
  - 6/32 reops
  - No exc, 14 good, 8 fair, 9 poor
- Cordasco: 2002 Grade I-II (4.5 years)
  - grade 1 & 2A 95% success (same as no tear !)
  - grade 2B: 38% failed

# Be Careful What you Debride....

- You may regret it later.....



# Surgical Results: ASD & Open Repair

|                |     |
|----------------|-----|
| – Itoi 1992:   | 82% |
| – Miller 1996: | 95% |
| – Weber 1999:  | 94% |
| – Fakuda 1996  | 94% |
| – Wright 1996  | 85% |

# DATA: Summary

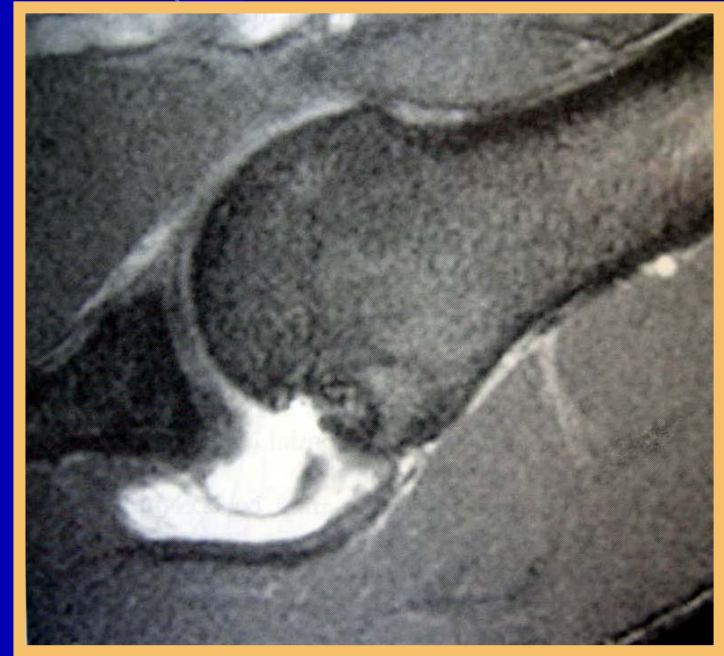- Debridement works for small partial tears  
Grade 1AB, 2A
- No significant difference between  
debridement and ASD for these tears
- Completing tear + repair gives better results  
for more significant partial tears especially  
bursal sided 2B, all grade 3
- *NOTE: NO GOOD DATA YET ON  
ARTHROSCOPIC PARTIAL REPAIRS !!*

# Treatment Recommendations

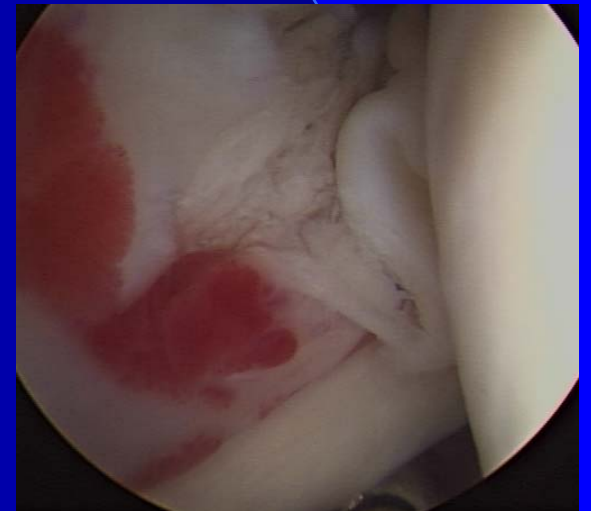
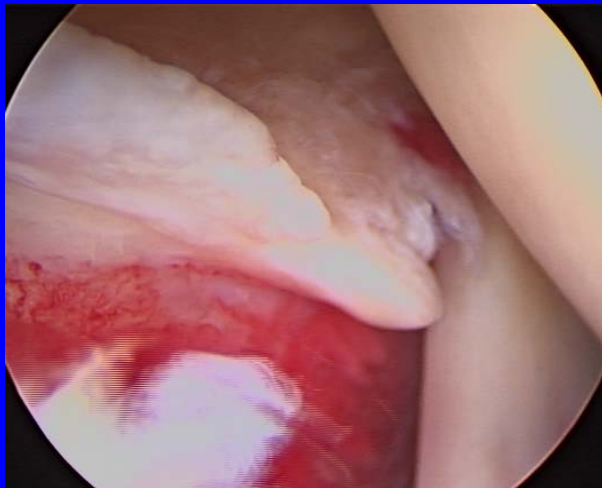
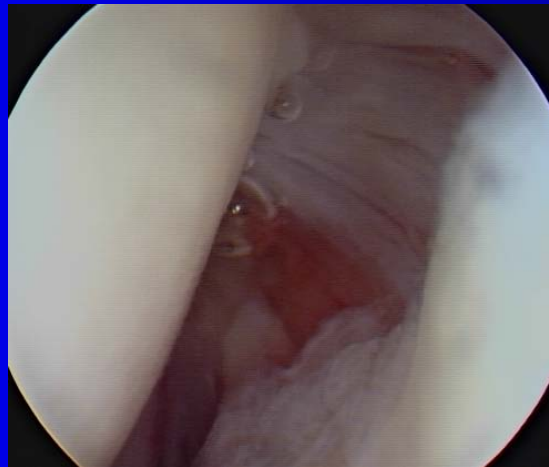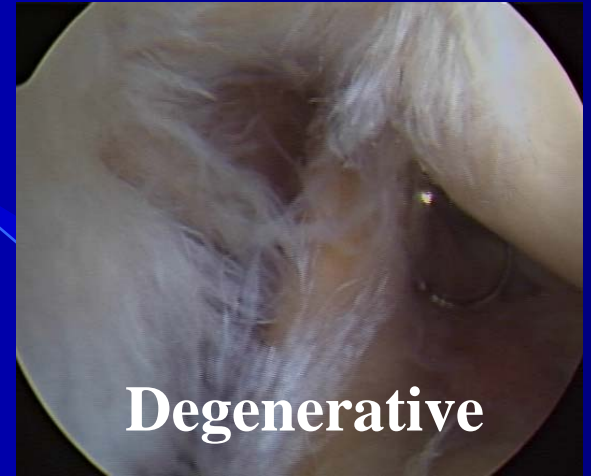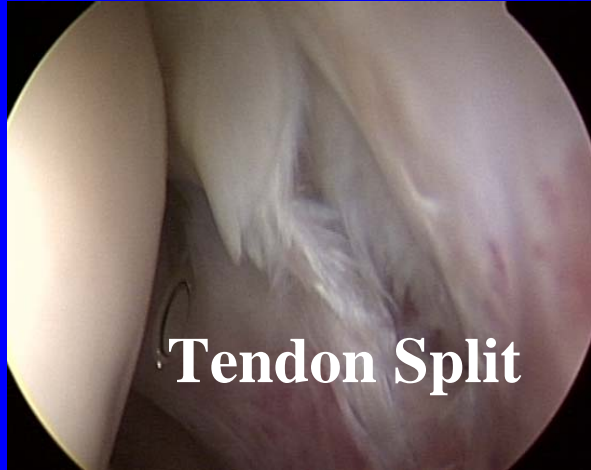
- Articular:
  - <50% Debride
  - > 50% Consider Repair
- Bursal:
  - <25% Debride
  - >25 % Consider Repair
- *Consider: activity level, dominant arm and morbidity of repair !*

# Articular Partial Thickness Tears of the RTC: Decision Making

- Evaluate type/shape of tear
- Evaluate Footprint
- Measure depth of tear



# Articular Tear Classification

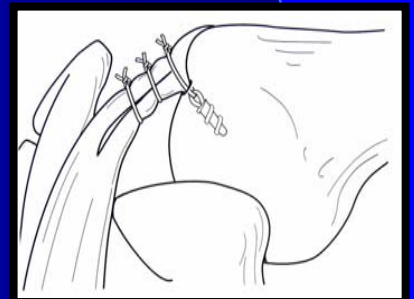
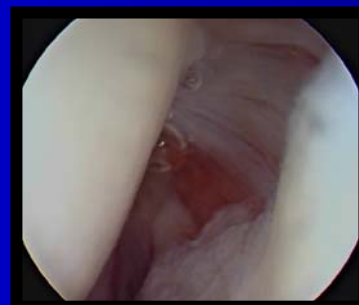
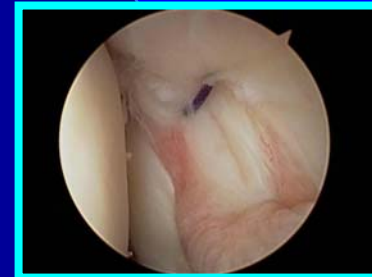
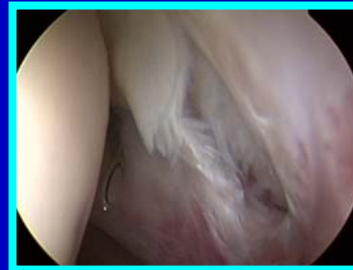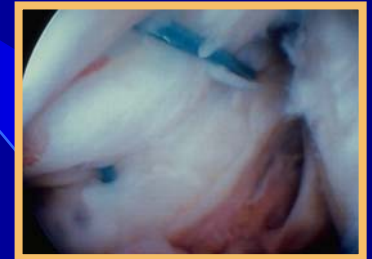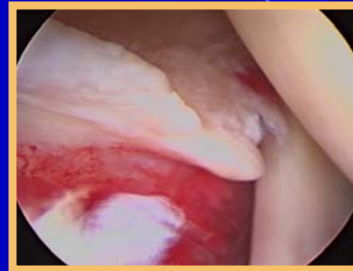**Delamination**

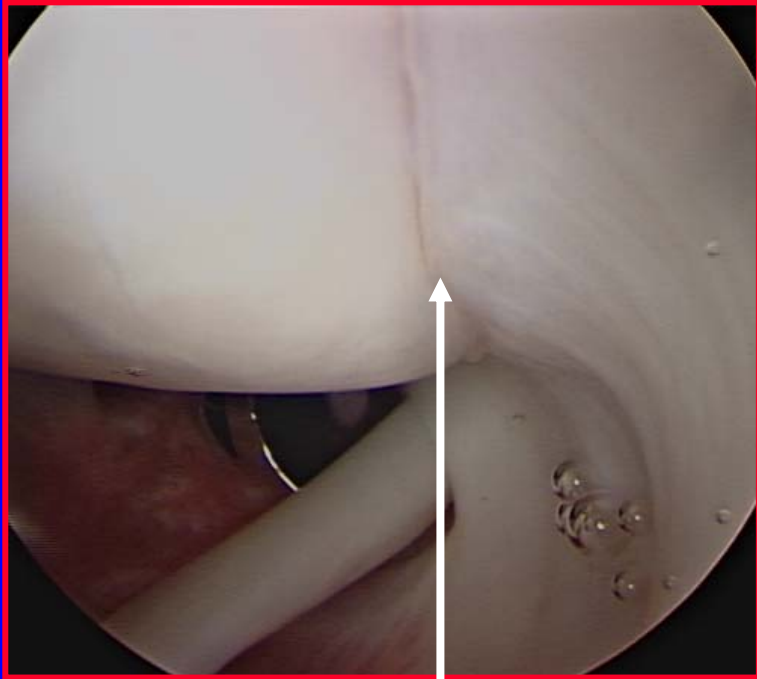
**“T” shaped Tear**

# Articular Tears: Partial Repair

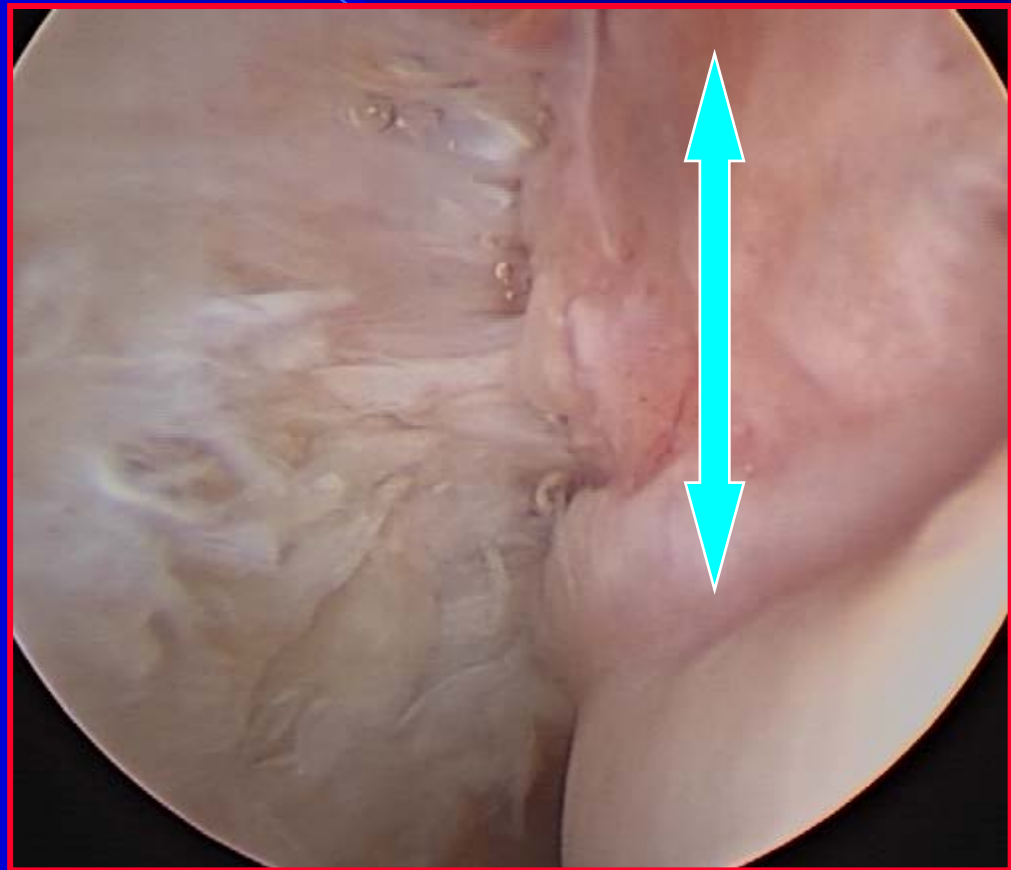
- Delamination:
  - Repair to remaining bursal cuff
- Split:
  - Side to side repair
- Avulsion
  - Measure thickness
  - Abrade bony bed
  - Repair footprint
    - Do not over tighten undersurface only !



# Measuring Depth of Tear



**Footprint**

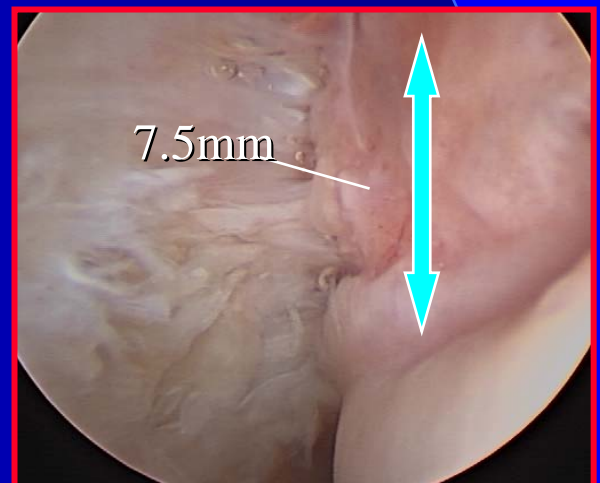
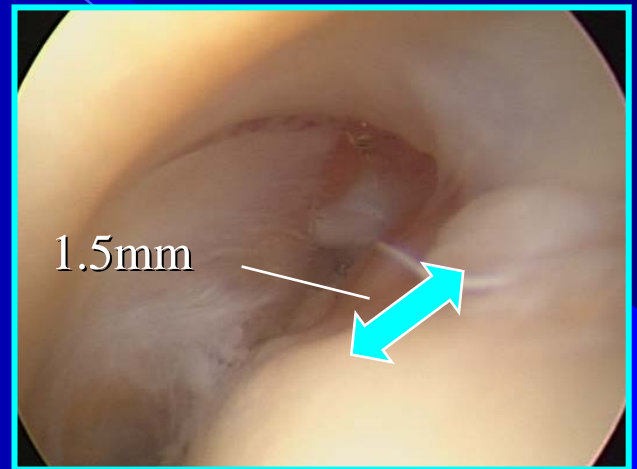


# How to Measure Depth of Tear: Avulsion

## Nottage Method *(Arthroscopy 2004)*

- Avg normal distance from tendon to articular margin:  
1.5mm
- Measure distance from undersurface tear to articular margin  
7.5mm
- Subtract 1.5mm  
= 6mm
- This # divided by normal tendon thickness = % torn

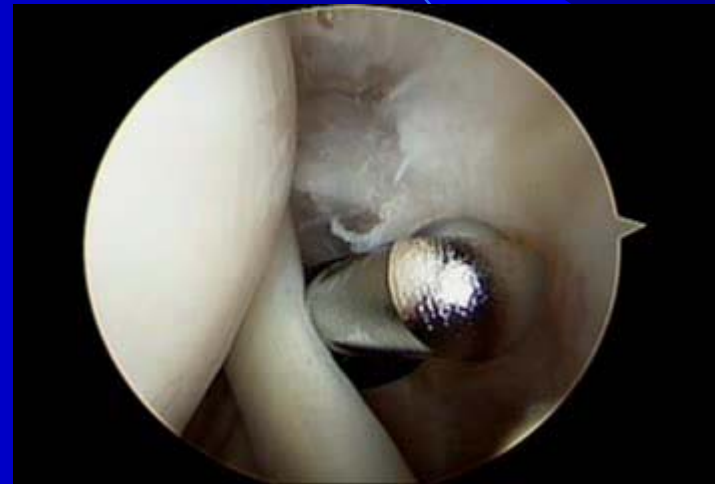$$6 \text{ mm}/12\text{mm} = 50\% \text{ tear}$$



# How to Measure Depth of Tear?

## Tissue loss

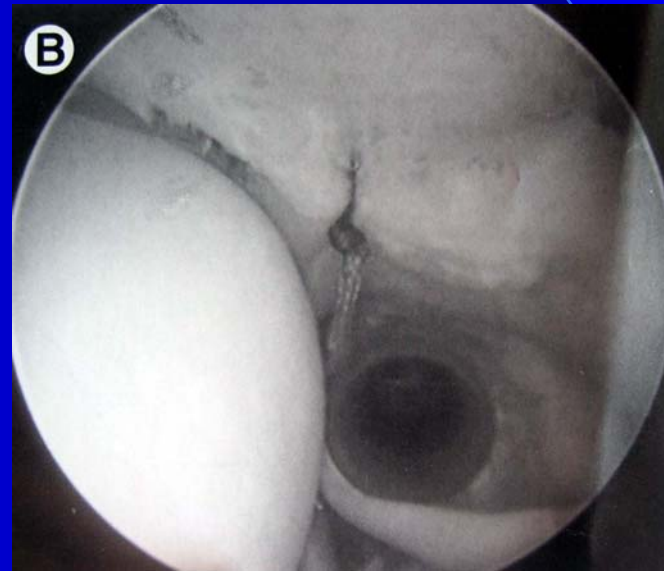
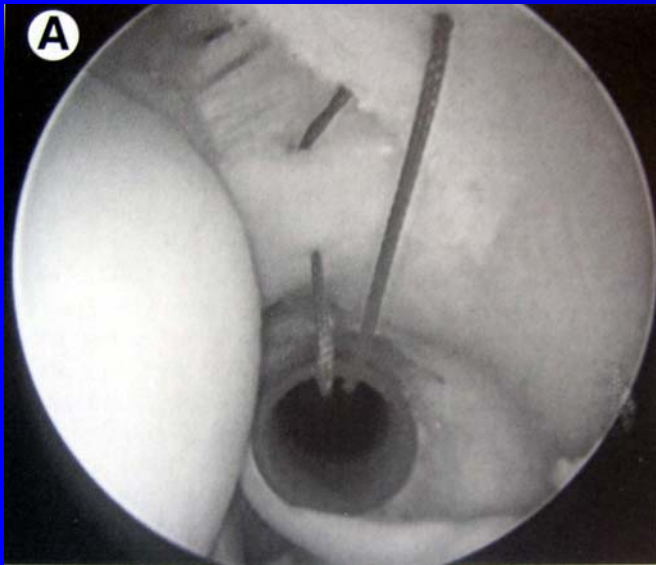
- 1) Debride damaged tissue
- 2) Suture marker
- 3) “Poor man’s” depth guage



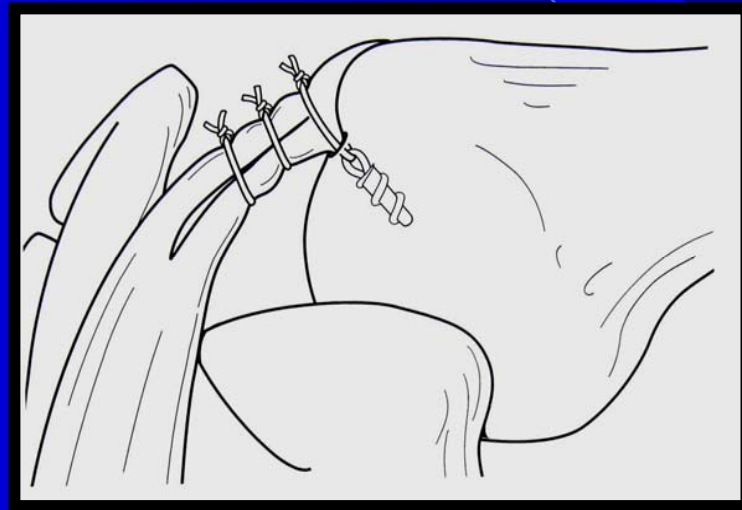
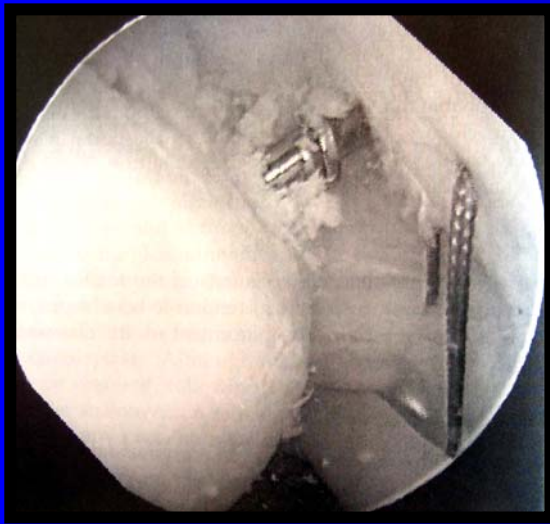
# Case Examples

Repair of Partial Thickness Tears

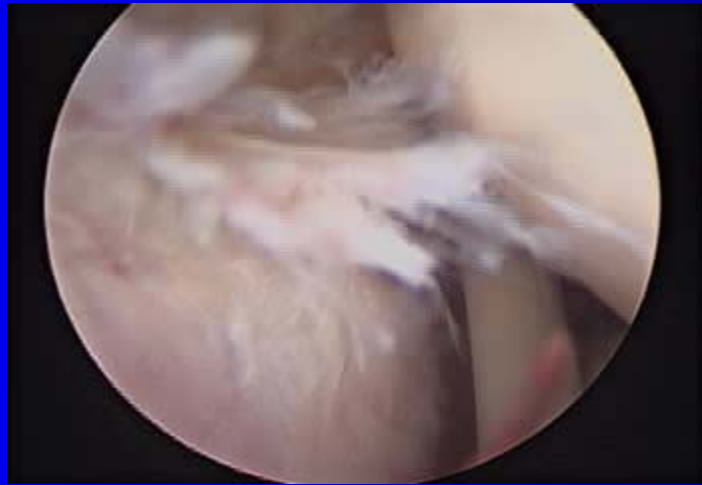# Articular Split Tear: Partial Articular Repair Side to Side



# Articular “T” Tear: Partial Articular Repair Undersurface to bone

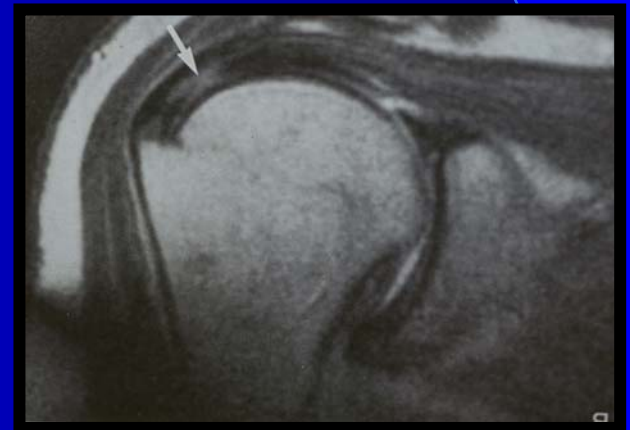
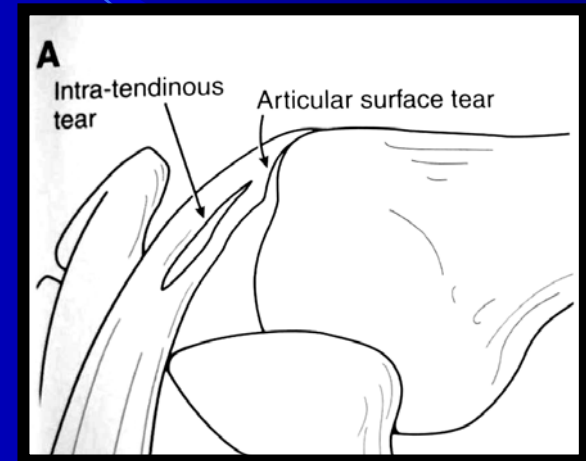


# Articular Avulsion: Partial Articular Repair: Transtendon

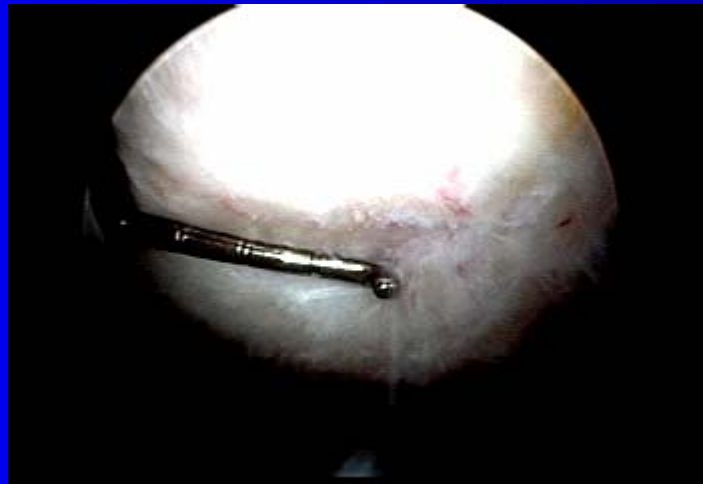


# Type of Tear: Intrasubstance

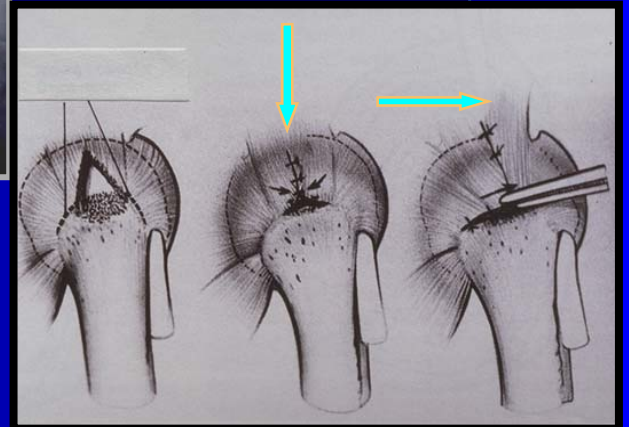
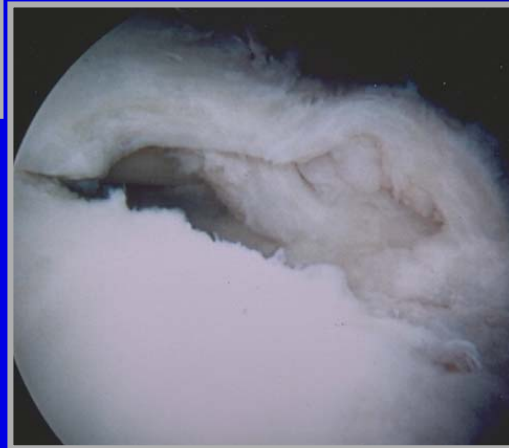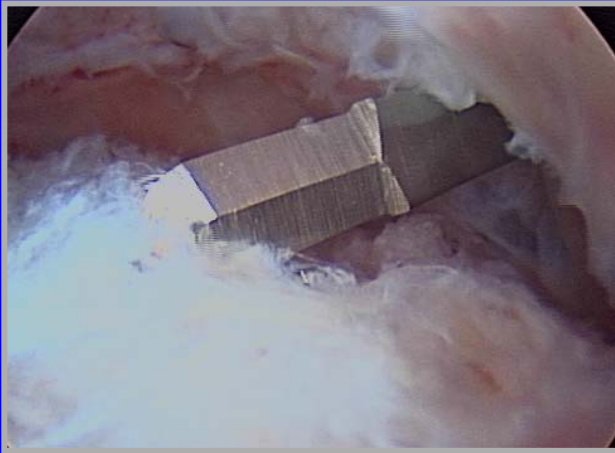
- When is this significant ?
- When/how do you treat ?
- MRI inaccurate:
- Intra-operative DX



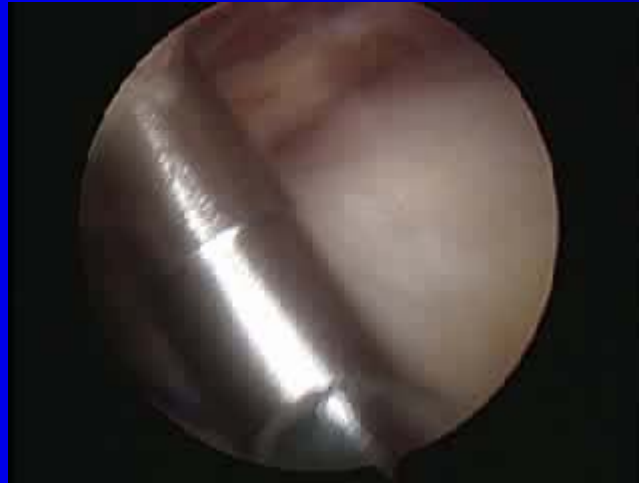# Decision Making: Probing Intrasubstance tears



# Complete the Tear & Repair

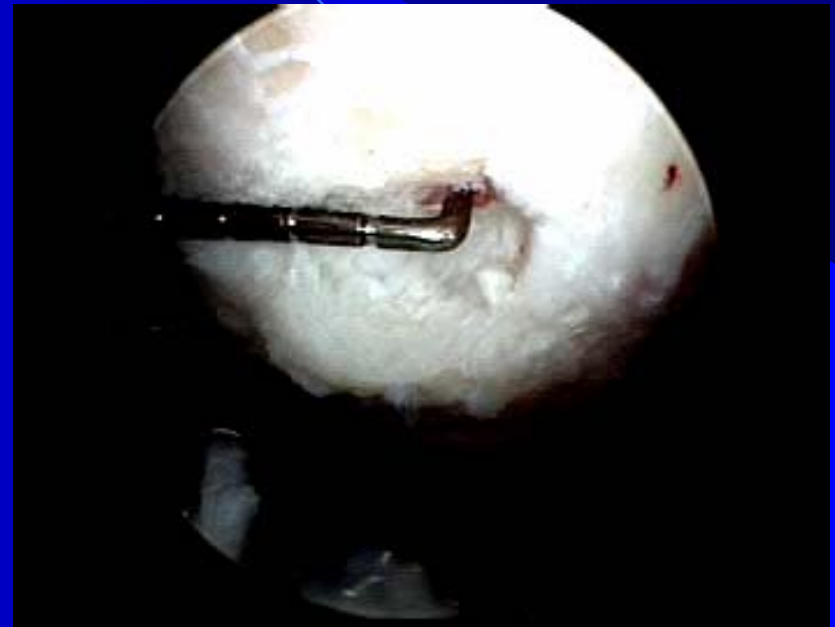


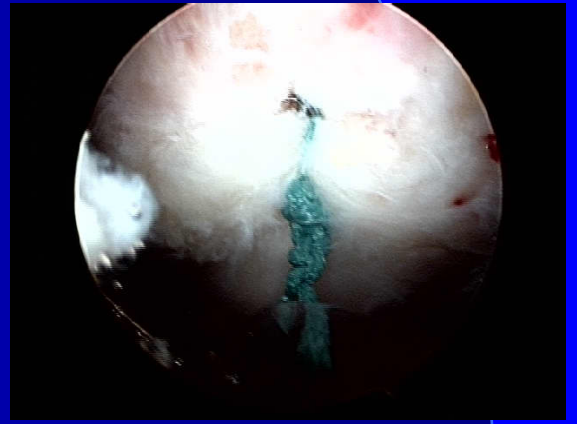
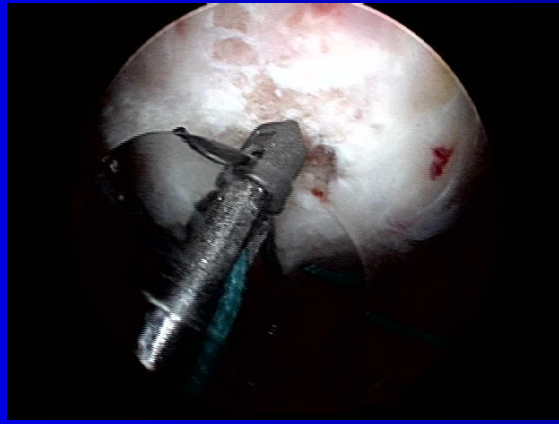
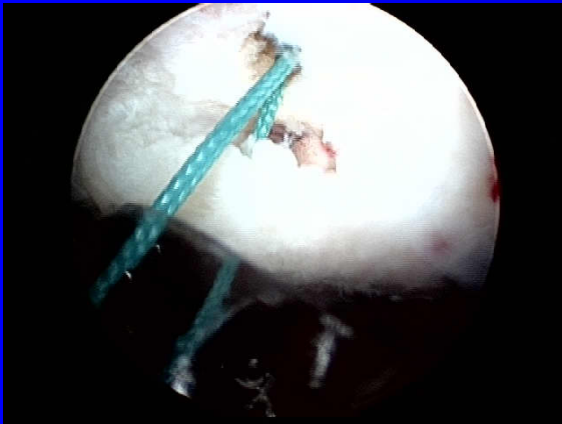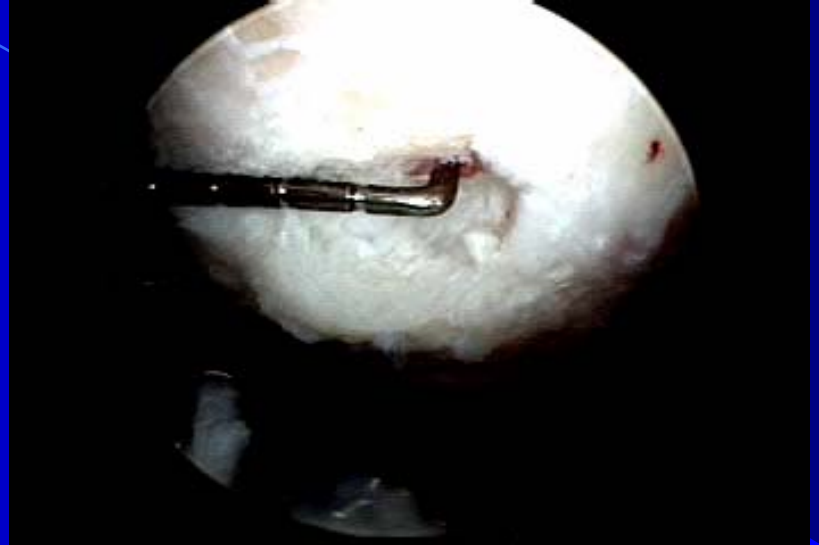
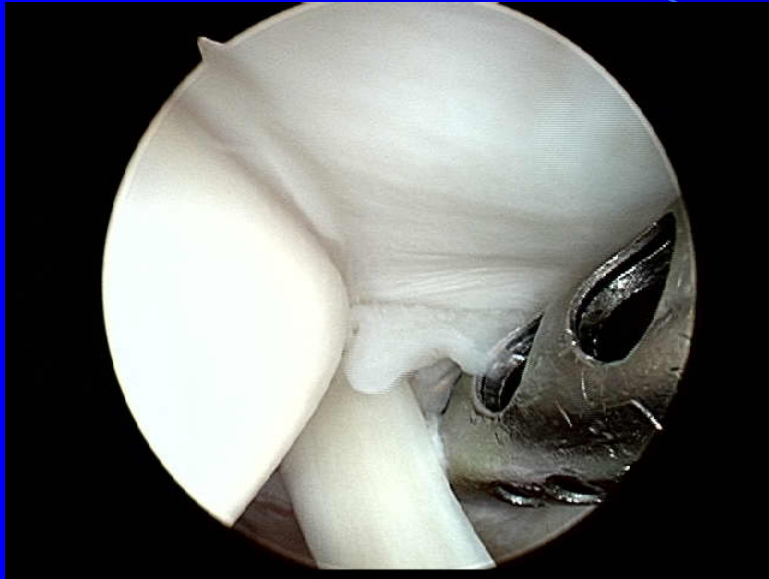
# IntrasubstanceTear: Video

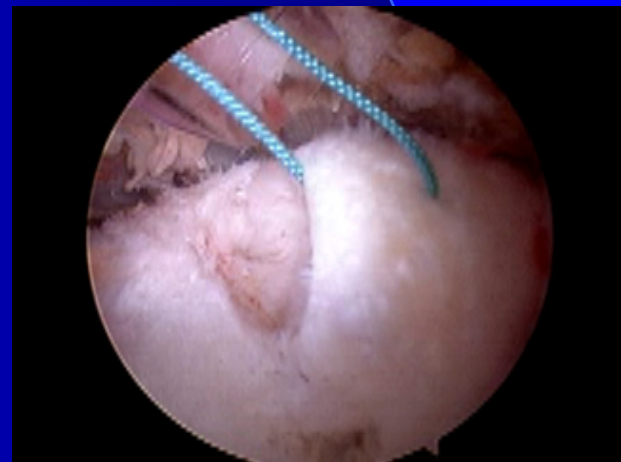
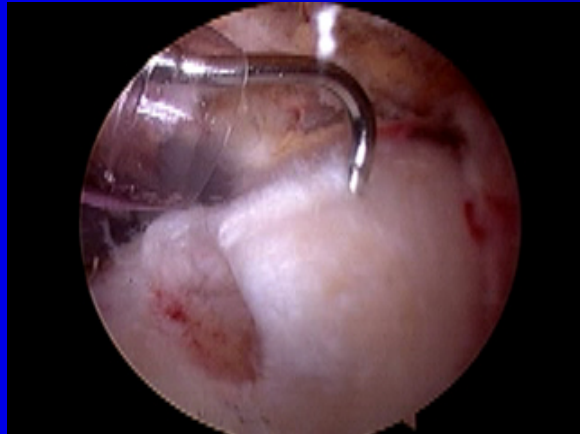
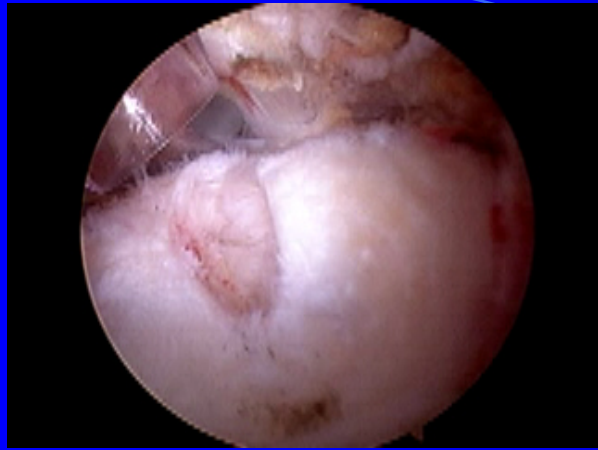


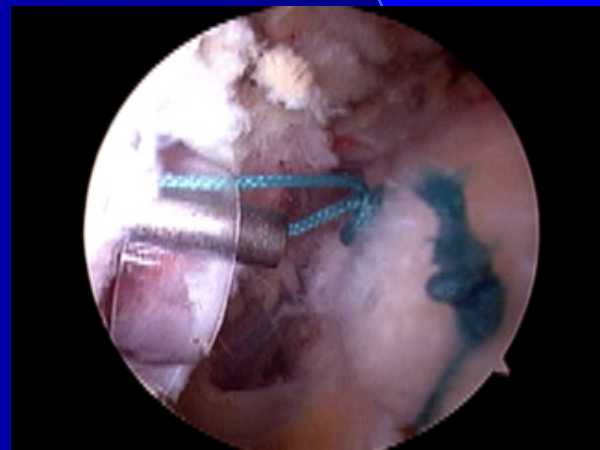
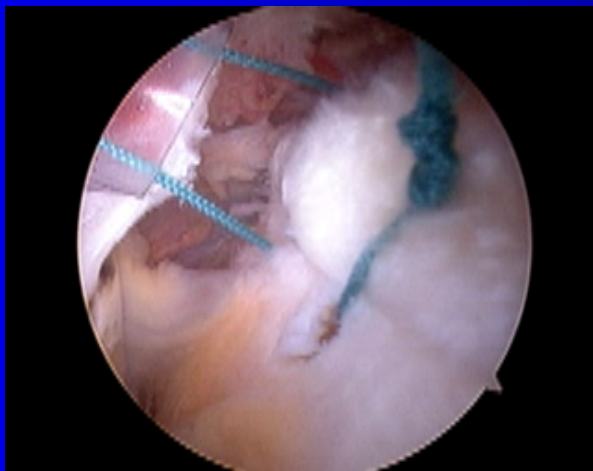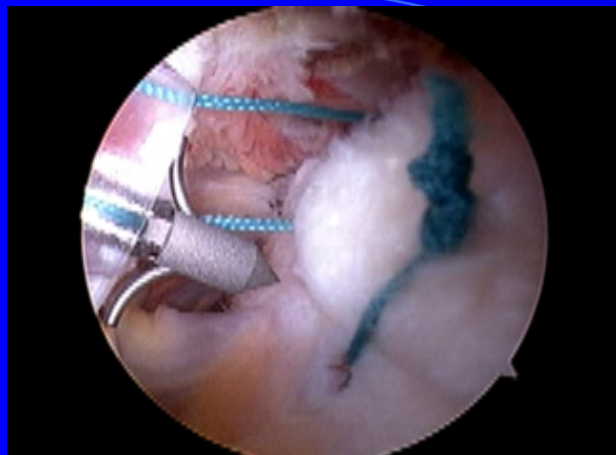# Partial Bursal Side Tear: Repair Technique

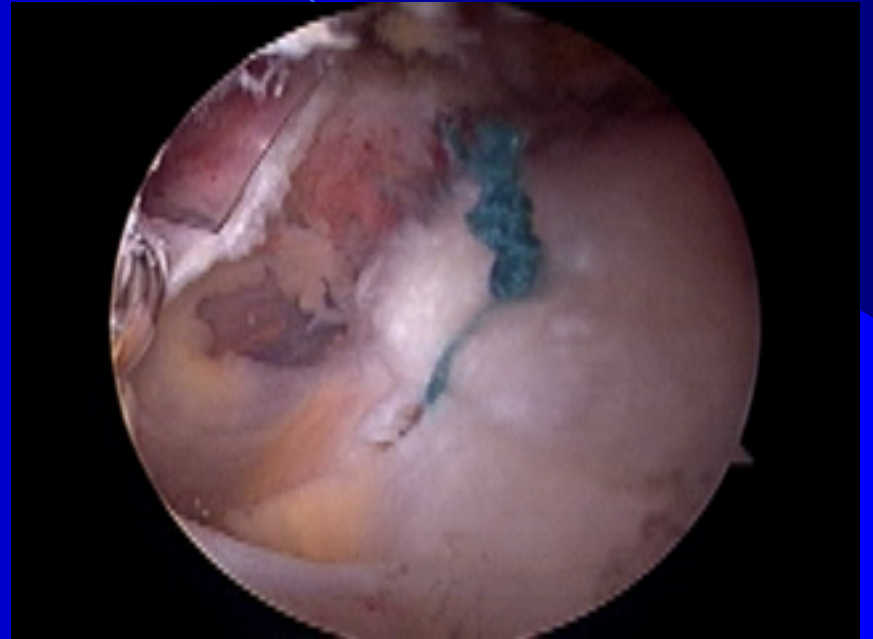
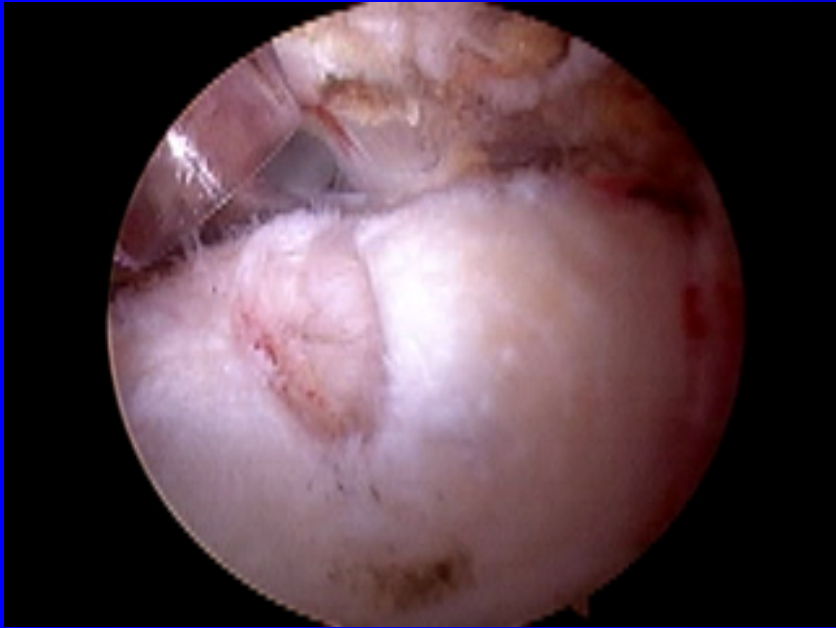
- same as full thickness tear











# Conclusion:

- Significant partial tears do not heal and probably enlarge
- Results of repair are better than ASD + debridement for significant partial tears
- Repair most Type 3 tears
- Consider repair Type 2 B tears

# However.....

- Remember
  - Many patients still do well with debridement
  - Consider morbidity of repair vs. debridement
  - Take into account age, activity level, dominant arm
- Unanswered questions....
  - Completing tear and repair seems to work- BUT...
    - Does partial repair improve results ?
    - Effect of uneven tension on repaired partial tear ?

Sometimes repairing is worse...



Than removing.....

# THANK YOU

