

Long-term Failure of Thermal Shrinkage for Laxity of the Anterior Cruciate Ligament

Jeffrey Halbrecht,* MD

From the Institute for Arthroscopy and Sports Medicine, San Francisco, California

Background: Appropriate treatment for anterior cruciate ligament laxity, owing to partial tears of the native ligament or lax reconstruction, is unclear. Studies suggest that a significant percentage of these untreated tears may progress to complete tears or the patient may develop additional injuries to the meniscus or articular cartilage. Shrinkage of the ligament or graft using thermal energy has been proposed as a solution for this problem.

Purpose: To evaluate the long-term results using thermal energy to shrink laxity of the anterior cruciate ligament.

Study Design: Case series; Level of evidence, 4.

Methods: Nineteen patients with partial tears of the anterior cruciate ligament ($n = 14$) or stretched anterior cruciate ligament grafts ($n = 5$) underwent thermal shrinkage treatment. Fourteen were available for follow-up at 1 and 5 years. At 1 year, there were 12 partial tears and 2 grafts available for evaluation. At 5 years, there were 10 partial tears and 4 grafts. Preoperative, postoperative, and intraoperative stability testing was performed using the KT-1000 arthrometer. Clinical results were evaluated using the Cincinnati and Lysholm scoring systems.

Results: Intraoperative shrinkage averaged 2.12 mm (17%, $P < .0001$). At 1 year, 12 of the 14 patients remained stable (86%) with a negative Lachman test result and mean KT-1000 arthrometer maximum side-to-side score of 1.29 mm ($P < .001$). The 2 failed shrinkages were partial tears of the native anterior cruciate ligament. For these 12 patients, Cincinnati scores improved from 53 to 89 ($P < .0001$), and Lysholm scores improved from 55 to 89 ($P < .0003$). At 5-year follow-up, 11 of 13 patients had gone on to complete failure (85%, $P < .002$; 8/9 partial tears and 3/4 grafts).

Conclusion: Thermal shrinkage provides short-term benefit in the treatment of anterior cruciate ligament laxity but leads to catastrophic failure in the majority of patients at long-term follow-up. We can no longer recommend this procedure for the treatment of anterior cruciate ligament laxity.

Keywords: anterior cruciate ligament (ACL); partial tear; shrinkage; stretched graft

Considerable controversy surrounds the diagnosis and treatment of ACL laxity resulting from partial tearing of the native ACL or a lax reconstruction. There is no consensus on the criteria for establishing the diagnosis of a partial tear of the ACL, and therefore the methods and results of treatment vary widely. Several differing studies suggest that a significant number of these tears may go on to become complete tears or the patient may develop additional injuries to the meniscus or articular cartilage.^{3,5,13} Noyes et al, in particular, found that patients with more than 50% disruption of the ACL had a greater than 50% risk of progression to complete failure.¹³

*Address correspondence to Jeffrey Halbrecht, MD, Institute for Arthroscopy and Sports Medicine, 2100 Webster Street, Suite 331, San Francisco, CA 94115 (e-mail: Halbj@aol.com).

Presented at the interim meeting of the AOSSM, San Francisco, California, March 2004.

No potential conflict of interest declared.

Although modern techniques of ligament reconstruction have resulted in reduced morbidity from surgery, complications may still occur. It would therefore appear desirable to pursue a less invasive technique of treatment such as tightening the lax ACL in situ, if this alternative could be proved effective. Because collagen shortens in response to heat,^{1,6} one possible treatment option would be to shrink the lax ligament using thermal energy.

Although a number of authors have demonstrated success with attempted shrinkage of the ACL,^{7,8,22,23} others have shown a significant risk of failure with this treatment.^{4,10}

The purpose of this study was to determine if radiofrequency electrothermal shrinkage could be used to effectively treat patients with ACL laxity caused by acute partial tearing of the native ACL or a lax reconstruction.

MATERIALS AND METHODS

Between 1997 and 1999, 200 patients were treated for ACL injury at the private practice of the lead author.

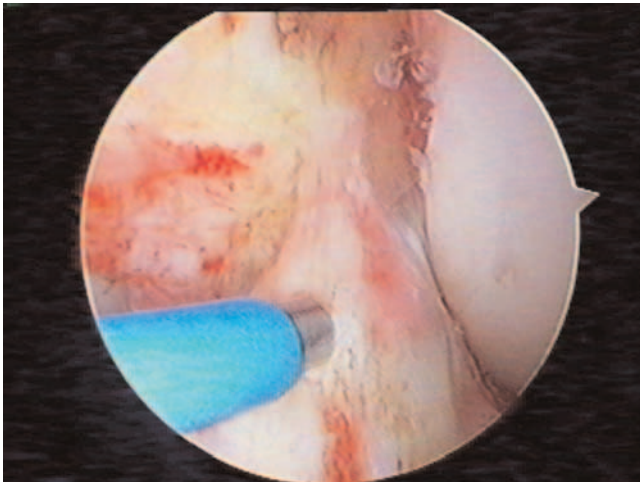


Figure 1. Striped painting technique used for thermal shrinkage procedure. Note attempt to leave areas of vascularity.

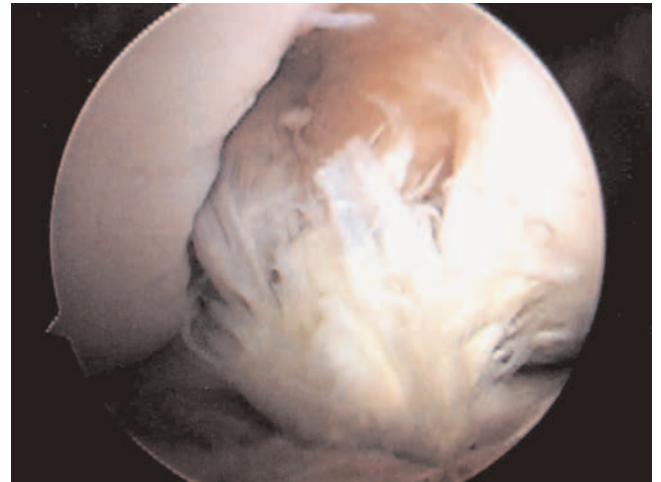


Figure 2. Example of a failed ACL thermal shrinkage, with complete ligament disruption.

Patients with acute partial tears of the ACL, patients with chronic partial tears, and patients with laxity of a reconstructed ligament were included in the study. Nineteen patients qualified for the study and agreed to the proposed treatment and follow-up. In this original group, there were 14 partial tears of the native ACL and 5 stretched grafts. The study design was approved by the hospital's Institutional Review Board, and all patients consented to participate in the study. Patients were evaluated at 1 year and at 5 years postoperatively to assess the short- and long-term efficacy of this procedure.

To be included in the study, patients had to have a clinical examination of less than a 1+ Lachman test result and a negative or trace pivot-shift result, as well as at least 50% ligament or graft integrity at arthroscopy, with intact bony attachment at both the femur and tibia. Patients with meniscal tears were included, but those with more complex injuries were excluded. Twelve patients were men and 7 were women with a mean age of 36 years (range, 23-52 years).

At 1 year, 14 of the original 19 patients were available for follow-up. Of the original 19 patients, 1 patient died from unrelated causes, and 4 patients were lost to follow-up. Of the remaining 14 patients, there were 12 partial tears of the ACL and 2 stretched grafts. Patients were evaluated with KT-1000 arthrometer (MedMetric Corp, San Diego, Calif) testing, the Cincinnati knee score, and the Lysholm score. There were 7 associated meniscal repairs and 3 partial meniscectomies performed at the index surgery.

At 5-year follow-up, 13 of the original 19 patients were also available. Nine of these 14 were the same patients who were available at 1 year. There were 9 partial tears of the native ACL and 4 stretched grafts.

Because of the retrospective nature of this study, not all data points were available for all patients. The data available are presented in Table 1.

All shrinkages were performed using a monopolar radiofrequency device set at 67°C and 40 W of power (Oratec Interventions Inc, Menlo Park, Calif).²³ The probe

was applied to obtain maximum shrinkage using a striped "painting" technique over the anterior surface of the ligament (Figure 1). This method attempts to leave untreated areas of ligament between areas exposed to heat shrinkage to preserve vascularity. Care was taken to avoid circumferential heating to maintain vascular integrity.

Patients underwent intraoperative KT-1000 arthrometer testing before and after shrinkage while under anesthesia to determine the initial amount of stability obtained at time zero.

Postoperative instruction was provided by the surgeon and therapist to protect the shrunken ligament. Immediately after surgery, patients were immobilized in a locked hinged knee brace at 25° of flexion and kept non-weightbearing for 3 weeks. At 3 weeks, patients were allowed to begin range of motion and weightbearing as tolerated with the brace. At 6 weeks, all patients were transitioned into a functional ACL brace for another 6 weeks, for a total of 3 months of protection. Impact, cutting, and twisting sports were prohibited for 6 months.

Failure of the procedure was determined by arthroscopic confirmation of a disrupted ACL (Figure 2) with an end point of reconstruction or a KT-1000 arthrometer manual maximum of >3 mm with a positive pivot-shift result. Success of the procedure was determined by a KT-1000 arthrometer test that demonstrated continued stability with a <3 mm side-to-side difference by the KT-1000 arthrometer manual maximum.

RESULTS

Preoperative Testing

Patients were examined under anesthesia before surgery. All partial tears and stretched grafts had a 1+ Lachman test result, and 6 patients had a trace pivot shift.

The mean preoperative side-to-side difference in the KT-1000 arthrometer manual-maximum drawer measured

TABLE 1
Demographic, Clinical, and Arthrometer Data for ACL Shrinkage Patients^a

Patient No.	Injury Type	Age, y	Sex	Cincinnati Score			Lysholm Score			KT-1000 Arthrometer Maximum Injured - Normal, mm			KT-1000 Arthrometer Maximum Injured - Knee vs Value of Knee Before Treatment, mm			5-Year Final Status	
				Pre-operative	1 Year	5 Years	Pre-operative	1 Year	5 Years	Pre-operative	1 Year	5 Years	Pre-operative	1 Year	5 Years		
1	Native ACL	34	Female	NA	Failed	Failed	NA	Failed	Failed	Failed	6	Failed	Failed	Failed	Failed	Failed	Reconstructed
2	Native ACL	39	Male	47	Failed	Failed	85	82	Failed	Failed	4	Failed	Failed	-1	Failed	Failed	Reconstructed
3	Native ACL	39	Male	26	Failed	Failed	26	95	Failed	Failed	5	Failed	Failed	-2	Failed	NA	Reconstructed
4	Native ACL	39	Female	83	Failed	Failed	75	93	Failed	Failed	4	Failed	Failed	-1	Failed	-4	Reconstructed
5	Native ACL	39	Male	NA	Failed	Failed	NA	Failed	Failed	Failed	0	Failed	Failed	-1	Failed	-2	Reconstructed
6	Native ACL	30	Male	64	87	78	38	85	87	87	6	2	3	-5	4	NA	Stable
7	Native ACL	29	Male	59	93	NA	55	94	NA	NA	2	NA	NA	NA	NA	-2	Lost to follow-up
8	Native ACL	48	Male	67	93	NA	53	85	NA	NA	2	NA	NA	-1	NA	-1	Lost to follow-up
9	Graft	23	Female	NA	NA	NA	NA	NA	Failed	Failed	5	NA	Failed	NA	Failed	NA	Reconstructed
10	Native ACL	24	Female	NA	NA	Failed	NA	NA	Failed	Failed	NA	Failed	Failed	NA	Failed	NA	Reconstructed
11	Native ACL	37	Male	NA	NA	NA	NA	NA	NA	NA	5	NA	NA	NA	NA	-2	Deceased
12	Native ACL	52	Male	NA	NA	47	NA	NA	62	NA	NA	NA	NA	NA	NA	NA	Stretched, failed
13	Native ACL	27	Male	48	100	NA	49	100	NA	NA	2	0	NA	-3	NA	-2	Lost to follow-up
14	Graft	47	Male	NA	NA	Failed	NA	NA	Failed	Failed	9	6	Failed	-2	Failed	-2	Reconstructed
15	Native ACL	37	Male	35	91	NA	46	85	NA	NA	1	-3	NA	-3	NA	-2	Lost to follow-up
16	Graft	38	Female	37	63	58	73	81	61	61	-3	-5	-4	-4	-5	-5	Stable
17	Graft	27	Male	21	61	NA	5	74	NA	NA	5	5	NA	-2	NA	-3	Lost to follow-up
18	Native ACL	35	Female	45	90	Failed	62	94	Failed	Failed	3	2	Failed	-2	Failed	-2	Reconstructed
19	Native ACL	34	Female	58	97	85	75	89	Failed	Failed	4	1	7	NA	Failed	-3	Stretched, failed
Mean, all		35.72		49.17	85.75	67.00	53.50	88.08	70.00	70.00	3.29	1.29	2.50	-2.23	-0.50	-2.12	
Mean, ACL only		35.38		53.20	90.50	66.00	56.40	90.20	74.50	74.50	3.12	1.00	4.67	-2.06	4.00	-1.80	
Mean, graft only		31.80		29.00	62.00	58.00	39.00	77.50	61.00	61.00	3.88	2.17	-4.00	-2.67	-5.00	-3.17	

^aNA, not available and indicates missing data points because of the retrospective nature of the study.

3.29 mm (range, 0-9 mm), and the mean total laxity was 12.9 mm (range, 9-19 mm).

Intraoperative Testing

After the thermal shrinkage procedure, each knee was retested intraoperatively using a sterile KT-1000 knee ligament arthrometer. The manual-maximum value decreased by 2.12 mm (range, 1-5 mm; $P < .0001$). This decrease represented a mean shrinkage of 17% (2.12/12.6; $P < .0001$). Graft shrinkage averaged 3.17 mm compared to 1.80 mm for partial tears of the native ACL.

Short Term: 1 Year. At 1-year follow-up, 14 patients were available for review. There were 12 acute or subacute partial tears of the native ACL and 2 stretched grafts (1 patellar tendon autograft and 1 Achilles allograft, both with good tunnel position). There were 2 gross failures that went on to reconstruction. Both were partial tears of the native ACL. Of the remaining 12 patients, the results were satisfactory at this early follow-up. KT-1000 arthrometer results revealed a mean manual-maximum drawer (injured – normal) of 1.29 mm ($P < .01$) (Table 1). Two of the grafts had KT-1000 arthrometer maximum values of 5 and 6 but were still counted as successes at this stage because they were both 2 mm tighter than preoperatively and were clinically improved. Mean Cincinnati scores improved from 49.17 preoperatively to 85.75 postoperatively ($P < .01$). The Lysholm score improved from 53.5 preoperatively to 88.08 postoperatively ($P < .01$). All patients had full range of motion, and all were satisfied and would do the procedure again.

Long Term: 5 to 7 Years. Thirteen patients of the original group of 19 patients were available for follow-up at 5 years. This subgroup included 9 of the 14 patients who were available at 1 year and 4 others from the original group of 19. There were 10 partial tears of the ACL and 4 grafts. Eight of 9 partial tears and 3 of the 4 grafts had gone on to complete failure. Six of these patients were confirmed failures as determined by an end point of reconstruction. The other 2 patients were determined to have failed based on increased KT-1000 arthrometer manual-maximum values (4 and 7 mm, respectively; Table 1) and positive pivot-shift results on clinical examination, but they elected not to undergo reconstruction. The overall failure rate was 85% (11/13, $P < .002$) (Table 2).

The remaining 2 patients remained stable as judged by a KT-1000 arthrometer manual-maximum side-to-side difference of <3.0 mm. Mean Lysholm and Cincinnati scores for these 2 patients showed a trend toward lower scores, but no statistical significance could be determined ($n = 2$).

DISCUSSION

Partial Tears of the ACL

The prognosis for partial tears of the ACL seems to depend on the extent of the tear. Several authors have shown that

TABLE 2
Long-term Failure Rate^a

	No. Failed	Failure Rate, %
Partial tears	8/9	89
Stretched grafts	3/4	75
Total	11/13	85 ($P < .002$)

^aMinimum 5-year follow-up (range, 5-7 years). There were 14 patients: 9 partial tears and 4 stretched grafts.

tears involving greater than 50% of the ACL are more likely to go on to failure,^{3,5,13} and tears involving less than 50% of the ligament have a better prognosis.^{15,18} In one study of 32 patients with partial ACL tears left untreated, Noyes et al reported that 38% progressed to full tears, with most tears occurring at more than 2 years. In this study, the risk of progression correlated to percentage tearing of the ACL. Patients with 50% tears had a 50% risk of progression, patients with 75% tears had an 86% risk of progression, and patients with a 25% tear had a 12% risk of progression.¹³ However, other authors have been unable to correlate percentage tearing to clinical results^{3,5} or have failed to mention percentage tearing at all.^{15,18}

The expected clinical outcome for partial tears of the ACL is controversial. A number of authors have reported less than optimal clinical results in patients with partial tears of the ACL treated nonoperatively. Buckley et al³ reported on 25 patients with partial tears of the ACL and demonstrated excellent to good results in only 60% and fair to poor results in 40%. Seventy-two percent continued to have activity-related symptoms. Similarly, Barrack et al showed that of 35 partial tears, only 23% had an excellent result, 29% had a good result, 17% had a fair result, and 31% had a poor result.²

However, other authors have reported a more optimistic outcome. Messner and Maletius reported a mixed prognosis in their long-term follow-up of patients with partial tears of the ACL.¹¹ At 18- to 25-year follow-up, of 22 patients evaluated, all patients had decreased their activities from contact sports to physical fitness. Eight had a 1+ Lachman test result, 2 had a 2+ Lachman test result, and 1 had a positive pivot-shift result. Ten of the 22 had Fairbank changes. However, none of the patients went on to ligament reconstruction, and the authors' conclusion was that partial ACL tears did not lead to "major" instability at 20-year follow-up.

Sommerlath et al also suggested a more optimistic prognosis in their series of 19 patients with 9- to 15-year follow-up,²¹ concluding that in general, patients did well with nonoperative treatment. However, at long-term follow-up, more than 50% of the patients demonstrated decreased sports participation and slight signs of degenerative osteoarthritis. Despite a mean increase at long-term follow-up of 1 mm in laxity based on arthrometer testing, none of the patients went on to reconstruction, and the Lysholm score remained good at 93.

In a review of the existing literature on partial ACL tears, Rauch et al also seemed to support a moderately

optimistic outcome, averaging 84% of the patients with good results, with 6% going on to subsequent ACL reconstruction and 5% going on to meniscus surgery. They concluded that the results of studies demonstrated a high variability and were mostly retrospective and that further prospective controlled studies were necessary.¹⁷

A critical review of the literature, as discussed above, suggests that although some patients will do well with a partial tear of the ACL, there is an increased risk of progression to complete rupture in patients with more extensive tears. In addition, there appears to be an increase in radiographic evidence of degenerative osteoarthritis and decreased functional scores at long-term follow-up in many patients. Based on these findings, surgical intervention would seem to be indicated if stability could be obtained with a relatively minor procedure.

Thermal Shrinkage

A monopolar radiofrequency probe transmits radiofrequency energy from the probe through tissue to a grounding pad. Heat penetration in tissues with low impedance, such as ligamentous tissue, causes collagen denaturation and shortening, along with associated cell death to a depth of 3 to 4 mm.¹

Thermal energy is capable of shortening ligamentous tissue by disrupting its collagen cross-links and unwinding its triple helix structure. Initial biomechanical strength is diminished and returns to close to normal by 12 weeks.^{1,6}

The ability of heat to shrink collagen both *in vivo*⁶ and *in vitro*²⁴ has been proven by several authors, with shrinkage to 70% of the resting length demonstrated using an Achilles tendon model *in vitro* in a saline bath at 70°C.²⁴ However, excessive heating may cause significant tissue damage. Localized *in vitro* shrinkage of the patellar tendon resulted in an immediate reduction in tensile strength, as measure by load to failure, to one third that of historical controls.²⁴ The exact shrinkage effect on collagen is dependent on many factors, including method of heat delivery, temperature of the probe, and length of heat application.¹

Initial thermal effects cause an initial significant drop in tissue stiffness, reduction in viscoelastic properties, and histological changes of hyalinization and denatured tissue.^{1,6} Loss of tissue stiffness maximizes at 50% to 60% at 2 weeks, gradual improvement occurs by 6 weeks, and it returns to almost normal mechanical properties by 12 weeks.⁶

ACL Shrinkage Studies

Several other authors have evaluated the short-term effects of thermal shrinkage for ACL laxity. Thabbit, in 1998, was the first to report on a combined series of patients with ACL laxity and graft laxity treated with monopolar electrothermal shrinkage.²³ He immobilized his patients at 25° and reported 23 of 25 patients with good and excellent results. Only 2 patients were considered fail-

ures at 1.5-year follow-up: 1 patient with a complete failure and 1 with a 4-mm KT-1000 arthrometer difference.

In 2002, Kahn et al reported on 38 patients with native or reconstructed ligaments and associated laxity treated with radiofrequency thermal energy.⁸ At a mean follow-up of 17 months, the side-to-side KT-1000 arthrometer difference was 2.3 mm, with the Lysholm knee scores improving from 52 to 74. Only 1 patient had failed treatment at this point and required a reconstruction.

Indelli et al recently reported on 28 partial tears of the ACL treated with monopolar shrinkage at a minimum 2-year follow-up, with only 1 early failure at 8 weeks and with 26 knees demonstrating a KT-1000 arthrometer difference between 0 and 2 mm.⁷

Spahn and Schindler examined 14 patients with elongated ACL grafts treated with bipolar electromagnetic energy at a mean of 9.4 months. Lysholm scores improved from 35.9 to 88.5, and tibial translation was reduced from 13 to 2 mm.²²

Most recently, Carter et al reported their short-term results on a series of 18 patients, including 7 grafts and 11 partial tears.⁴ At 20-month follow-up, 11 of 18 patients had gone on to failure (6/7 grafts and 5/11 partial tears). They concluded that this procedure had limited application, although it may have a role in the treatment of acute partial tears of the native ACL.

Several case reports regarding the failure of thermal shrinkage of the ACL have also been reported, one with "autodigestion" and complete resorption of a hamstring autograft due to suspected heat necrosis²⁰ and the second reporting "spontaneous simultaneous" rupture of both ACL and PCL after radiofrequency thermal treatment of both ligaments.¹⁶ Failure of isolated heat shrinkage has also recently been reported for the PCL.¹⁴

A number of animal studies have been performed suggesting poor results with thermal shrinkage of the ACL. Scheffler et al were able to create an ACL elongation model in a sheep.¹⁹ After elongating the native ACL, thermal shrinkage was able to restore stability to almost normal at time zero. However, despite protected postoperative loading with an Achilles tenotomy, at 24 weeks, restretching of the shrunken ligaments had occurred with a significantly lower stiffness and failure load for the radiofrequency-treated ligaments.

Kondo et al shrank pig ACL *in vitro* using an electrothermal device at either 28 or 45 W and an application time of 30 or 60 seconds. Although shrinkage of up to 26% was obtained, all groups demonstrated a significant reduction in stiffness under tensile testing.⁹ Finally, Lopez and Markel recently reported 100% failure after thermal shrinkage using a monopolar technique in a dog model, with all failures occurring by 55 days after surgery.¹⁰

Current Study

The current study confirms previous experimental and clinical data that found effective initial shrinkage of the ACL can be obtained using a monopolar electrothermal probe. Similar to some of the other published short-term

studies, our early follow-up data at 1 year suggest that this procedure can be effective in maintaining a stable knee at this short-term follow-up. However, our longer follow-up clearly indicates an extremely high catastrophic failure rate of 85% at 5 years. Even the remaining patients who did not go on to reconstruction or definitive failure showed a decrease in both Lysholm and Cincinnati scores and a trend toward increased laxity compared to their 1-year results, although scores remained improved compared to preoperative levels.

The increased long-term failure rate may be explained by a persistent mechanical weakness resulting from the effects of thermal treatment. Although some experimental studies have suggested that mechanical strength returns to almost normal by 12 weeks after thermal shrinkage,⁶ other studies have suggested that cyclic creep remains increased for longer periods.²⁵ Recent clinical data in the shoulder have also been reported suggesting long-term failure after thermal capsular shrinkage and have led to increased caution regarding its use for shoulder instability.¹² Our long-term follow-up data would suggest similar concerns for its use for ACL instability.

CONCLUSION

Although thermal shrinkage of a lax ACL is effective in shortening the ligament in the short term, longer term follow-up suggests an extremely high rate of catastrophic failure. Based on our data, we can no longer recommend this procedure.

REFERENCES

1. Barber FA, Uribe JW, Weber SC. Current applications for arthroscopic thermal surgery. *Arthroscopy*. 2002;18(suppl 18):40-50.
2. Barrack RL, Buckley SL, Bruckner JD, Kneisel JS, Alexander AH. Partial versus complete acute anterior cruciate ligament tears: the results of nonoperative treatment. *J Bone Joint Surg Br*. 1990;72:622-624.
3. Buckley SL, Barrack RL, Alexander AH. The natural history of conservatively treated partial anterior cruciate ligament tears. *Am J Sports Med*. 1989;17:221-225.
4. Carter TR, Bailie DS, Edinger SE. Radiofrequency electrothermal shrinkage of the anterior cruciate ligament. *Am J Sports Med*. 2002;30:221-226.
5. Fruensgaard S, Johannsen HV. Incomplete rupture of the anterior cruciate ligament. *J Bone Joint Surg Br*. 1989;71:526-530.
6. Hecht P, Hayashi K, Lu Y, et al. Monopolar radiofrequency energy effects on joint capsular tissue: potential treatment for joint instability. An in vivo mechanical, morphological and biomechanical study using an ovine model. *Am J Sports Med*. 1999;27:761-771.
7. Indelli PF, Dillingham MF, Fanton GS, Shurman DJ. Monopolar treatment of symptomatic anterior cruciate ligament instability. *Clin Orthop*. 2003;407:139-147.
8. Kahn SA, Sherman OH, DeLay B. Thermal treatment of anterior cruciate ligament injury and laxity with its imaging characteristics. *Clin Sports Med*. 2002;21:701-711.
9. Kondo E, Yasuda K, Tohyama H, Kudoh T, Aoki Y, Minami A. The effect of electrothermal shrinkage on biomechanical properties of the anterior cruciate ligament. *Arthroscopy*. 2003;19(suppl 1):48-49.
10. Lopez MJ, Markel MD. Anterior cruciate ligament rupture after thermal treatment in a canine model. *Am J Sports Med*. 2003;31:164-167.
11. Messner K, Maletius W. Eighteen- to twenty-five-year follow-up after acute partial anterior cruciate ligament rupture. *Am J Sports Med*. 1999;27:455-459.
12. Miniaci A, McBirnie L. Thermal capsular shrinkage for treatment of multidirectional instability of the shoulder. *J Bone Joint Surg Am*. 2003;85:2283-2287.
13. Noyes FR, Moar LA, Moorman CT III, McGinniss GH. Partial tears of the anterior cruciate ligament: progression to complete ligament deficiency. *J Bone Joint Surg Br*. 1989;71:825-833.
14. Oaks DA, McAllister DR. Failure of heat shrinkage for treatment of a posterior cruciate ligament tear. *Arthroscopy*. 2003;19:E1-E4.
15. Odensten M, Lysholm J, Gillquist J. The course of partial anterior cruciate ligament ruptures. *Am J Sports Med*. 1985;13:183-186.
16. Perry JJ, Higgins LD. Anterior and posterior cruciate ligament rupture after thermal treatment [case report]. *Arthroscopy*. 2000;16:732-736.
17. Rauch G, Wirth T, Dörner P, Griss P. Is conservative treatment of partial or complete anterior cruciate ligament ruptures still justified? Analysis of the recent literature and a recommendation for arriving at a decision. *Z Orthop Ihre Grenzgeb*. 1991;129:438-446.
18. Sandberg R, Balkfors B. Partial tears of the anterior cruciate ligament: natural course. *Clin Orthop*. 1987;220:176-178.
19. Scheffler SU, Schoenfelder V, Hunt P, Chwastek H, Suedkamp N, Weiler A. Mechanical and histological analysis of the chronically relaxed ACL after thermal radiofrequency shrinkage in a sheep model. Paper #93 John Joyce award finalist. *Arthroscopy*. 2003;19(suppl):47-48.
20. Sekiya JK, Golladya GJ, Wojtyls EM. Autodigestion of a hamstring anterior cruciate ligament autograft following thermal shrinkage. *J Bone Joint Surg Am*. 2000;82:1454-1457.
21. Sommerlath K, Odensten M, Lysholm J. The late course of acute partial anterior cruciate ligament tears: a nine to fifteen year follow-up evaluation. *Clin Orthop*. 1992;281:152-158.
22. Spahn G, Schindler S. Tightening elongated ACL grafts by application of bipolar electromagnetic energy (ligament shrinkage). *Knee Surg Sports Traumatol Arthrosc*. 2002;10:65.
23. Thabib G. The arthroscopic monopolar radiofrequency treatment of chronic anterior cruciate ligament instability. *Oper Tech Sports Med*. 1998;6:157-160.
24. Vangsnæs CT Jr, Mitchell W III, Nimni M, Erlich M, Saadat V, Schmotzer H. Collagen shortening: an experimental approach with heat. *Clin Orthop*. 1997;337:267-271.
25. Wallace AL, Hollinshead RM, Frank CB. Creep behavior of a rabbit model of ligament laxity after electrothermal shrinkage in vivo. *Am J Sports Med*. 2002;30:98-102.