

Arthroscopic Meniscal Repair Using the BioStinger

F. Alan Barber, M.D., Donald H. Johnson, M.D., and Jeffrey L. Halbrecht, M.D.

Purpose: Biodegradable devices are available for all-inside meniscal repairs. One device, the BioStinger (Linvatec, Largo, FL), is made of molded poly-L-lactic acid. The purpose of this study was to evaluate the effectiveness of and any adverse events associated with meniscus repair using this device. **Type of Study:** Nonrandomized prospective cohort study. **Methods:** A prospective, consecutive, 3-center meniscal repair series using BioStingers (group 1), vertical inside-out sutures (group 2), or hybrid repairs combining BioStingers and sutures (group 3) was studied. Lysholm, Tegner, Cincinnati, and IKDC activity scores were obtained and clinical outcomes and adverse events documented. **Results:** There were 85 patients who underwent 89 meniscus repairs with an average 26.5 months of follow-up. There were 47 BioStinger repairs (group 1), 29 suture repairs (group 2), and 13 hybrid repairs (group 3). The tear length was statistically greater for the hybrid repair group ($P < .5$). There were 73 repairs associated with anterior cruciate ligament reconstructions and 12 repeat arthroscopies were performed. Meniscal healing failed in 6 knees (4 in group 1, 0 in group 2, and 2 in group 3). The meniscal healing failed in 7% of those associated with anterior cruciate ligament reconstructions. Mean Tegner scores improved from 2.8 to 6.3, the final IKDC activity score was 3.2 out of 4, the mean Lysholm score improved from 51 to 88, and the mean Cincinnati score improved from 44 to 84. Two BioStinger repair cases had joint-line tenderness from device migration confirmed by magnetic resonance imaging. No tenting of the skin or articular cartilage scuffing was observed. **Conclusions:** The success rate for the 29 suture repairs was 100% and for the 47 BioStinger repairs was 91%. These preliminary results are consistent with other repair techniques. **Level of Evidence:** Level II, Therapeutic Prospective Cohort Study. **Key Words:** Meniscus—Repair device—Bioabsorbable—BioStinger.

Meniscal repair recognizes the importance of the meniscus in knee stability, load transmission, joint lubrication, and articular cartilage nutrition.^{1,2} After significant meniscus loss, degenerative knee changes develop.³ Consequently, meniscal repair is commonly practiced for peripheral longitudinal tears possessing a good blood supply. Several recently developed all-inside meniscal repair devices are available for peripheral longitudinal tears in the “red-white” or “red-red” zones.⁴⁻⁹ These devices are made

from various biodegradable materials and with different designs including tacks, staples, screws, and self-adjusting anchors. One device, the BioStinger (Linvatec, Largo, FL), is made of molded poly-L-lactic acid (PLLA). Its cannulated design allows insertion over a needle trocar. This needle allows reduction and positioning of the meniscus tear fragments before inserting the device. The study hypothesis was that this device would successfully repair longitudinal meniscus tears. The purpose of this study was to evaluate the effectiveness of and record any adverse events associated with meniscus repair using the BioStinger meniscal repair device.

METHODS

Starting in 1998, a prospective multicenter study of consecutive patients undergoing arthroscopic meniscal repair was undertaken. Institutional review board approval was obtained at all participating centers. The

From the Plano Orthopedic and Sports Medicine Center (F.A.B.), Plano, Texas, U.S.A.; the Department of Orthopaedics, Carleton University (D.H.J.), Ottawa, Ontario, Canada; and Private Practice (J.L.H.), San Francisco, California, U.S.A.

Address correspondence and reprint requests to F. Alan Barber, M.D., Plano Orthopedic and Sports Medicine Center, 5228 West Plano Pkwy, Plano TX 75093, U.S.A. E-mail: knees2do@aol.com
© 2005 by the Arthroscopy Association of North America
0749-8063/05/2106-4120\$30.00/0
doi:10.1016/j.arthro.2005.03.002

initial study design called for a randomization of patients into either suture or BioStinger groups based on a specific code number. However, as the study progressed, this randomization broke down because of the observed inability of the BioStinger to completely repair some of the larger, longer, more anterior tears, resulting in the need for augmentation of these repairs with sutures and thus creating a third class of “hybrid” repairs containing both sutures and BioStingers. Additionally, some tears were located so far posteriorly (especially with the lateral meniscus) that the surgeon opted to use the BioStinger instead of sutures to avoid the potential for neurovascular injury to the patients. The result was a nonrandomized prospective consecutive series of meniscal repairs performed using the BioStinger (group 1), vertical inside-out sutures (group 2), or a hybrid repair combining both BioStinger and sutures (group 3). All patients were evaluated postoperatively by Lysholm,¹⁰ Tegner,¹¹ Cincinnati,¹² and IKDC activity scores at 6- to 12-month intervals. Data on results and adverse events were also collected and consolidated.

Inclusion criteria were patients with longitudinal meniscal tears in the red-red (<3 mm from the synovial meniscal junction) or red-white (3 to 5 mm from the synovial meniscal junction) zones of the meniscus (Fig 1). There were no age restrictions. An associated anterior cruciate ligament (ACL) reconstruction was permitted. Exclusion criteria were patients with previous meniscus surgery including repairs, and horizontal, transverse, or complex (flap) tears of the meniscus.

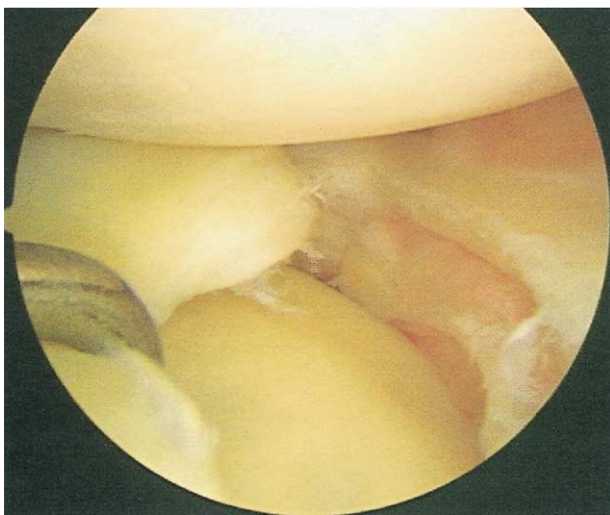


FIGURE 1. A longitudinal meniscal tear in the red-white zone chosen for repair.

Surgical Technique

The surgical technique for the BioStinger includes the establishment of the standard arthroscopic portals. The meniscal healing potential was enhanced by various techniques including rasping¹³ and peripheral rim trephination using the meniscal vascular punch (Arthrex, Naples, FL). Fibrin clot¹⁴ or marrow stimulation¹⁵ were not used. The BioStinger insertion cannula is passed through the appropriate portal to reach the tear. The needle trocar onto which the cannulated BioStinger is loaded is then advanced 2 to 3 mm and inserted into the inner rim of the meniscus (Fig 2A). With the needle catching the meniscus inner rim, that portion of the meniscus tear is then positioned in correct alignment to the peripheral rim portion. Once the appropriate reduction of the tear is achieved, the needle trocar is advanced fully into the peripheral rim to capture both sides of the meniscus tear (Fig 2B). The inserter needle is only 2 mm longer than the associated BioStinger to protect from peripheral over penetration while allowing for 2 mm of head recession. Next, the BioStinger is inserted into the tissue by fully depressing the plunger knob on the proximal end of the insertion instrument (Fig 2C). The BioStinger head is advanced until it slightly depresses the meniscal surface (Fig 2D). Multiple devices can be inserted if needed with a 5- to 10-mm distance between each device (Fig 3).

The inside-out meniscal repair technique used both No. 2-0 braided polyester sutures and No. 0 PDS sutures inserted with a zone specific cannula system (Linvatec), exiting through either a posteromedial incision or a posterolateral incision, and tied down on the capsule to avoid the neurovascular structures and capturing soft tissue. The curved cannulas of the zone specific system have a significantly smaller radius than the BioStinger inserter and allow for a much more anterior “reach” than that provided by the BioStinger insertion device.

The postoperative rehabilitation program was the appropriate ACL rehabilitation program for those repairs performed in conjunction with an ACL reconstruction.¹⁶ For meniscus repairs without ACL surgery, an accelerated program of exercise was used that included no postoperative bracing, full immediate weight bearing, and a return to pivoting sports when the patient showed no evidence of inflammation.¹⁷⁻¹⁹ The specific criteria for this were no effusion, full extension, and nearly full flexion (135°). Patients with meniscal repairs without an associated ACL reconstruction were not held back or subjected to any less

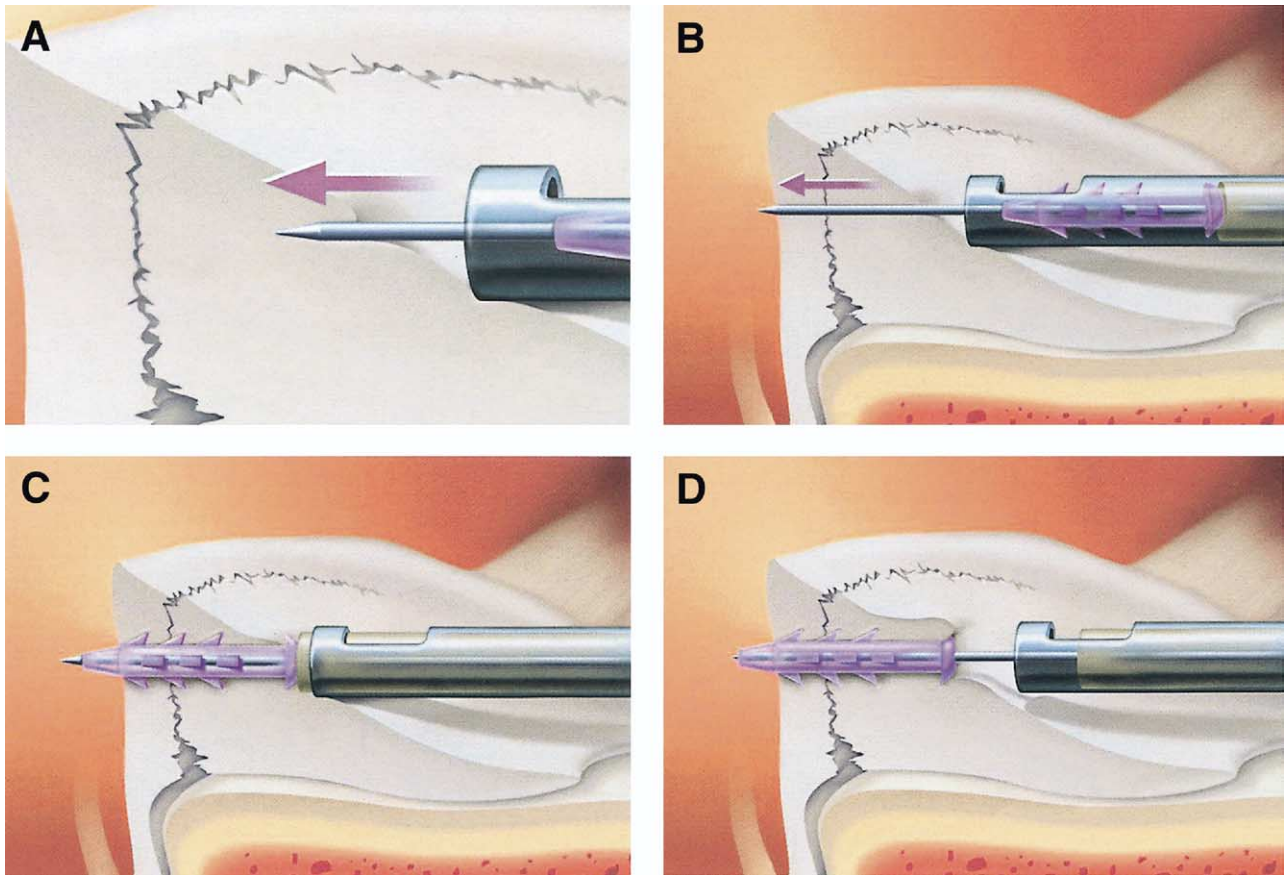


FIGURE 2. (A) The BioStinger needle trocar is advanced 2 to 3 mm and inserted into the inner rim of the meniscus. (B) Once the tear is reduced, the needle trocar is advanced to capture both sides of the meniscus tear. (C) Next the BioStinger is inserted into the tissue by fully depressing the plunger knob on the inserter. (D) The BioStinger head is advanced until it slightly depresses the meniscal surface.

aggressive a program than those patients undergoing an ACL reconstruction.

Statistical analysis of the results was carried out. Calculations between the differences of the means were performed by an analysis of variance and paired-sample Student *t* test, and those of the frequencies by the χ -square test (Fisher exact test). The significance level was chosen to be $P < .05$.

RESULTS

A total of 99 patients were admitted to the study and underwent meniscus repair by 3 different surgeons. Of these, 85 patients (86%) with 89 repairs were available with a minimum follow-up of 12 months and 14 were lost to follow-up. The average age was 27 years (range, 15 to 48 years) and the average follow-up was 26.5 months (range, 12 to 56 months); there were 54 male and 31 female patients. There were 47 pure

BioStinger repairs (group 1), 29 repairs using only sutures (group 2), and 13 hybrid repairs (group 3). Seventy-three of the 89 repairs were associated with ACL reconstructions (41 in group 1, 24 in group 2, and 8 in group 3). The remaining repairs were performed in ACL intact knees (5 in group 1, 5 in group 2, and 5 in group 3), or ACL unstable knees (1 in group 1). Persistent symptoms lead to repeat arthroscopies for 12 different repairs with failure of meniscal healing observed in 6 repaired menisci (4 of 47 in group 1, 0 of 29 in group 2, and 2 of 13 in group 3). Residual evidence of the BioStinger was apparent as far out as 16 months. In 1 case, 16 months after repair, meniscal healing was observed to be complete with a barely visible BioStinger and, notably, no articular cartilage scuffing (Fig 4). No statistical difference in healing was found between these groups ($P > .5$). Meniscal healing failed in 5 of the 73 cases with ACL reconstructions (7%) and the 1 case with an unstable

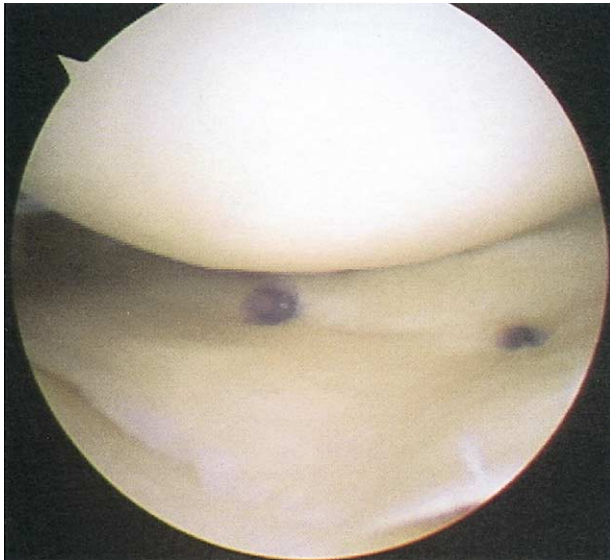


FIGURE 3. Multiple BioStingers were inserted if needed, spaced at 5- to 10-mm intervals.

ACL. The time intervals from surgery to failure ranged from 4 to 42 months (mean, 26 months).

The repairs were categorized by tear depth (red-red, red-white, or white-white) (Table 1). All the failures were found to occur in medial meniscus red-red repairs except for 1 lateral meniscus failure that was a white-white repair in an unstable (ACL-deficient)

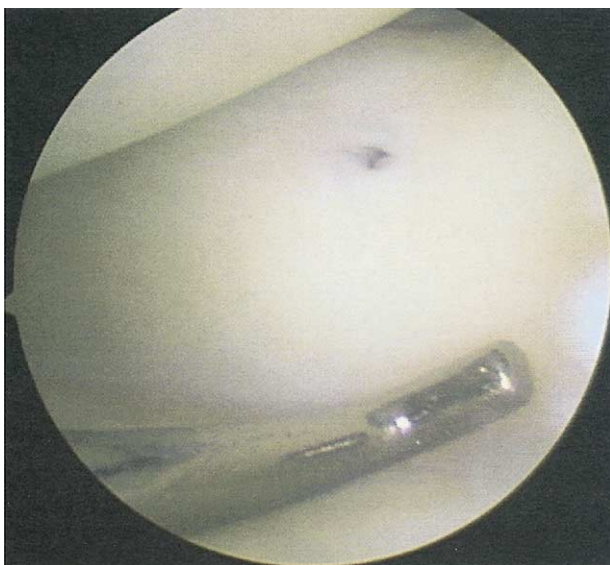

FIGURE 4. Meniscal healing is complete 16 months after repair. The BioStinger is barely visible and there is no articular cartilage scuffing.

TABLE 1. Depth of Tear for the Different Repair Groups

	Red-Red	Red-White	White-White
BioStinger	31	15	1
Suture	20	7	2
Hybrid	9	4	0

knee. The repairs were also categorized by the zone of the tear (e.g., anterior, middle, middle and posterior, posterior, full bucket-handle tear) (Table 2). All repair failures were tears located in the posterior third of the meniscus. There were a total of 23 lateral meniscus repairs with 1 failure (4%) and 66 medial meniscal repairs with 5 failures (8%). There was no statistical difference in the incidence of medial or lateral repairs ($P > .5$).

The length of the repairs was also recorded and analyzed. The average tear length was 20 mm. Tear lengths are reported in Table 3. The tear lengths of those repairs that failed ranged from 10 to 40 mm. The tear length was statistically greater for the hybrid repair group ($P < .5$), with 9 of the 12 tears that were 30 mm or more in length having this type of repair (hybrid). Both the suture and BioStinger repair groups included a full range of tear lengths including shorter tears.

The number of sutures or devices used was tabulated. The average number of sutures used for a repair was 2.9 (range, 1-9) for the suture repair group and 4.2 (range, 1-8) for the hybrid group, but this was not statistically significant. The average number of meniscal repair devices used in the BioStinger group was 2.1 (range, 1-4) and for the hybrid group was 2.4 (range, 1-4).

At the most recent follow-up visit, the mean Tegner score had improved from a preoperative score of 2.8 to 6.3 (6.4 in group 1, 6.3 in group 2, and 5.8 in group 3), and the IKDC activity score was 3.2 out of 4 (3.1 in group 1, 3.5 in group 2, and 3.1 in group 3). The mean Lysholm score improved from a preoperative score of 51 to 88 (88 in group 1, 87 in group 2, and 88

TABLE 2. Repair Zone for the Various Repair Techniques

	Anterior	Middle	Middle Posterior	Posterior	Complete
BioStinger	1	6	—	40	—
Suture	—	3	—	25	1
Hybrid	—	1	2	7	3

TABLE 3. *Tear Lengths for the Different Repair Techniques*

	10 mm	15 mm	20 mm	25 mm	30 mm	40 mm
Total	5	21	41	10	7	5
BioStinger	3	14	22	7	—	1
Suture	2	7	16	2	1	1
Hybrid	—	—	3	1	6	3

in group 3), and the mean Cincinnati score improved from a preoperative score of 44 to 84 (83 in group 1, 84 in group 2, and 84 in group 3). There were no statistical differences for Tegner, IKDC, Lysholm, or Cincinnati scores ($P > .5$).

Adverse events were tracked in all groups. There were no cases of infection. In 2 BioStinger repairs, joint-line tenderness was reported that was caused by device migration (confirmed by magnetic resonance imaging) into the peripheral soft tissue (Fig 5). In these cases, there was no tenting of the overlying skin and the BioStinger was seen lying parallel to the meniscus. Neither required removal of the BioStinger. There were no instances in which the BioStinger perforated the meniscus and did not hold, which would have required removal through the skin.

DISCUSSION

This is the first report of a prospective clinical experience with the BioStinger meniscal repair de-

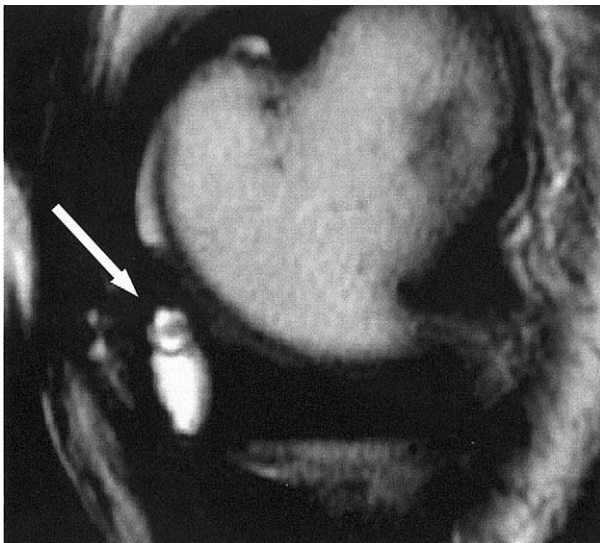


FIGURE 5. Magnetic resonance imaging shows the BioStinger (arrow) located posterior to the meniscus and parallel to it. The circle is the BioStinger cross piece and the dot in the center is the shaft.

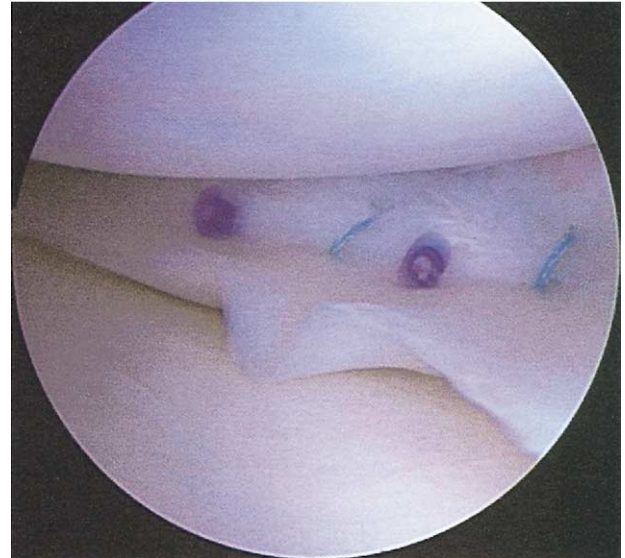

FIGURE 6. The hybrid repair used a combination of both sutures and repair devices.

vice. The actual usage of the device points out some of the limitations and strengths of meniscal repair devices. The BioStinger is very attractive for an extreme posterior lateral or posterior medial tear. The BioStinger can be inserted without additional incisions or the passing of sharp instruments through an area with important neurovascular structures. This not only avoids damage to these structures but problems with the capture of the posterior soft tissues by arthroscopically inserted sutures. In addition, the simplicity of this technique decreases operating time. On the other hand, for longer tears and especially the displaced meniscal tears, it is more difficult to achieve the same anatomic reduction and repair that is provided by sutures.

Tears involving the anterior third of the meniscus are also not repairable with meniscal repair devices because of the inability to access these zones with the associated insertion tools. Meniscal repair devices require the mastery of new instruments as well as the precise placement of the devices. Depending on which device is selected, a foreign body or prominent knot is left on or near the meniscal surface and the biomechanics of tear apposition by these devices has not been fully investigated. Finally, although a repair often requires fewer of these devices than sutures, their cost is significantly greater than a comparable number of arthroscopic meniscal sutures.

The hybrid repair using a combination of both sutures and BioStingers (Fig 6) seems to be an attractive

alternative to the pure suture or pure device repair in appropriately selected cases. Placing some BioStingers in a long peripheral longitudinal tear will “tack” it into position, allowing easier insertion of subsequent meniscal repair sutures. Also, the BioStinger seems well suited for the posterior horn portion of these long meniscus repairs to decrease the potential for complications. Repairs that used a combination of sutures and BioStingers (hybrid repairs) were statistically longer than the other repairs.

A weakness of this study is the lack of a second-look operation for a large portion of the patients. However, this reflects the successful clinical status of these cases and the difficulty in justifying reoperation for asymptomatic patients. Another weakness is the relatively short follow-up. Based on the experience of DeHaven et al.,²⁰ we anticipate that the early success rate may deteriorate over time and we intend to follow-up our patients for a longer period. Yet, this report with an average 26 months follow-up provides valuable insight into the postoperative course of meniscal repairs using the BioStinger. Additionally, the preliminary success rate reported here is consistent with other reports for both suture meniscal repairs and device repairs.^{4,7,16-21}

Biomechanical testing of this and other meniscal repair devices shows some variation in single-pull failure loads.^{8,22-25} Clinical reports that complement these biomechanical tests are as yet not available for most of the newer devices. Those clinical reports that do exist do not reveal any significant difference in healing rates for the various repair devices.^{4,7,21,26,27} This highlights the complexity of the question of what it actually takes to accomplish a successful meniscal repair. This report suggests that the BioStinger provides repair capabilities comparable to other meniscal repair devices reported to date.^{4,5,7,20,21,26,28}

It is well established that meniscal repair healing rates are higher when associated with an ACL reconstruction.²⁸⁻³⁰ This is probably because of the greater inflammatory healing response stimulated by the ACL reconstruction as well as the less degenerative nature of the peripheral longitudinal tear found with ACL tears. It was also observed in this study that healing rates were greater for the suture repairs (100%) than for the BioStinger repairs (91%). Whether this difference will be maintained after a longer follow-up period remains to be seen—it is expected that more meniscal failures will become apparent over time.²⁰

The BioStinger is a cannulated non-self-reinforced PLLA device. It contrasts significantly with the Linvatec Meniscus Arrow, which is rigid and will occa-

sionally migrate peripherally and even tent the skin. The BioStinger was not observed to do this. Instead, when found to lie peripherally, the BioStinger “turned” and lay flush with the capsule (Fig 4). The irritation associated with this migration usually disappeared after a period of 6 months. The biodegradable nature of this material will result in the complete absorption of these devices over time. At the time of repeat surgery, no articular cartilage excoriation or other problems reported with other devices^{7,31-37} were observed.

CONCLUSIONS

The purpose of this study was to evaluate the clinical effectiveness of the BioStinger meniscal repair device. At this point, the success rate for the suture repair is 100% and for the BioStinger device is 91%. This is a preliminary healing rate and will probably worsen over time as more failures become apparent.²⁰ Adverse events were encountered as with other repair devices,³⁸ including peripheral device migration,³⁹ but articular cartilage excoriation was not observed in this group.

REFERENCES

1. Lynch MA, Henning CE, Glick KR Jr. Knee joint surface changes: Long-term follow-up meniscus tear treatment in stable anterior cruciate ligament reconstructions. *Clin Orthop* 1983;172:142-153.
2. Yocum LA, Kerlan RK, Jobe FW, Carter VS, Shields CL Jr, Lombardo SJ, Collins HR. Isolated lateral meniscectomy: A study of twenty-six patients with isolated tears. *J Bone Joint Surg Am* 1979;61:338-342.
3. Fairbank TJ. Knee joint changes after meniscectomy. *J Bone Joint Surg Br* 1948;4:664-670.
4. Albrecht-Olsen PM, Bak K. Arthroscopic repair of the bucket-handle meniscus. *Acta Orthop Scand* 1993;64:446-448.
5. Haas AL, Schepis AA, Hornstein J, Edgar CM. Meniscal repair using the Fast-Fix all-inside meniscal repair device. *Arthroscopy* 2005;21:167-175.
6. Farg E, Sherman O. Meniscal repair devices: A clinical and biomechanical literature review. *Arthroscopy* 2004;20:273-286.
7. Nakame A, Deie M, Yasumoto M, Kobayashi K, Ochi M. Synovial cyst formation resulting from nonabsorbable meniscal repair devices for meniscal repair. *Arthroscopy* 2004;20 (suppl 2):16-19.
8. Barber FA, Herbert MA. Meniscal repair devices. *Arthroscopy* 2000;16:613-618.
9. Tsai AM, McAllister DR, Chow S, Young CR, Hame SL. Results of meniscal repair using a bioabsorbable screw. *Arthroscopy* 2004;20:586-590.
10. Lysholm J, Gillquist J. Evaluation of knee ligament surgery results with special emphasis on use of a scoring scale. *Am J Sports Med* 1982;10:150-154.
11. Tegner Y, Lysholm J. Rating systems in the evaluation of knee ligament injuries. *Clin Orthop* 1985;198:43-49.
12. Barber-Westin SD, Noyes FR, McCloskey JW. Rigorous sta-

- tistical reliability, validity, and responsiveness testing of the Cincinnati Knee Rating System in 350 subjects with uninjured, injured, or anterior cruciate ligament-reconstructed knees. *Am J Sports Med* 1999;27:402-416.
13. Uchio Y, Ochi M, Adachi N, Kawasaki K, Iwasa J. Results of rasping of meniscal tears with and without anterior cruciate ligament injury as evaluated by second-look arthroscopy. *Arthroscopy* 2003;19:463-469.
 14. Sethi PM, Cooper A, Jokl P. Technical tips in orthopaedics: Meniscal repair with use of an in situ fibrin clot. *Arthroscopy* 2003;19:E44 (available online at www.arthroscopyjournal.org).
 15. Freedman KB, Nho SJ, Cole BJ. Marrow stimulating technique to augment meniscus repair. *Arthroscopy* 2003;19:794-798.
 16. Barber FA. Accelerated rehabilitation for meniscus repairs. *Arthroscopy* 1994;10:206-210.
 17. Barber FA, Click SD. Meniscus repair rehabilitation with concurrent anterior cruciate reconstruction. *Arthroscopy* 1997;13:433-437.
 18. Mariani PP, Santori N, Adriani E, Mastantuono M. Accelerated rehabilitation after arthroscopic meniscal repair: A clinical and magnetic resonance imaging evaluation. *Arthroscopy* 1996;12:680-686.
 19. Shelbourne KD, Patel DV, Adsit WS, Porter DA. Rehabilitation after meniscal repair. *Clin Sports Med* 1996;15:595-612.
 20. De Haven KE, Lohrer WA, Lovelock JE. Long-term results of open meniscus repair. *Am J Sports Med* 1995;23:524-530.
 21. Barrett GR, Field MH, Treacy SH, Ruff CG. Clinical results of meniscus repair in patients 40 years and older. *Arthroscopy* 1998;14:824-829.
 22. Dervin GF, McBride D, Keene GCR, Downing K. Failure strengths of suture versus biodegradable arrow for meniscal repair. *Arthroscopy* 1997;13:387.
 23. Fisher SR, Markel DC, Koman JD, Atkinson TS. Pull-out and shear failure strengths of arthroscopic meniscal repair systems. *Knee Surg Sports Traumatol Arthrosc* 2002;10:294-299.
 24. Arnoczky SP, Lavagnino M. Tensile fixation strengths of absorbable meniscal repair devices as a function of hydrolysis time. An in vitro experimental study. *Am J Sports Med* 2001;29:118-123.
 25. Barber FA, Herbert MA, Richards DP. Sutures and suture anchors: Update 2003. *Arthroscopy* 2003;19:985-990.
 26. Ellermann A, Siebold R, Buelow JU, Sobau C. Clinical evaluation of meniscus repair with a bioabsorbable arrow: A 2- to 3-year follow-up study. *Knee Surg Sports Traumatol Arthrosc* 2002;10:289-293.
 27. Petsche TS, Selesnick H, Rochman A. Arthroscopic meniscus repair with bioabsorbable arrows. *Arthroscopy* 2002;18:236-253.
 28. Cannon WD, Vittori JM. The incidence of healing in arthroscopic meniscal repairs in cruciate ligament-reconstructed knees versus stable knees. *Am J Sports Med* 1992;20:176-181.
 29. Tenuta JJ, Arciero RA. Arthroscopic evaluation of meniscal repairs: Factors that effect healing. *Am J Sports Med* 1994;22:797-802.
 30. Ahn JH, Wang JH, Yoo JC. Arthroscopic all-inside suture repair of medial meniscus lesion in anterior cruciate ligament-deficient knees: Results of second-look arthroscopies in 39 cases. *Arthroscopy* 2004;20:936-945.
 31. Kelly JD 4th, Ebrahimpour P. Chondral injury and synovitis after arthroscopic meniscal repair using an outside-in mulberry knot suture technique. *Arthroscopy* 2004;20:e49-e52 (available online at www.arthroscopyjournal.org).
 32. Nagura I, Yagi M, Kokubu T, Yoshiya S, Kurosaka M. Generation of meniscal cyst after arthroscopic meniscal repair. *Arthroscopy* 2004;20:869-871.
 33. Barber FA. Articular cartilage damage, peripheral migration, and device failure as Meniscus Arrow complications. Case report. *Am J Knee Surg* 2000;13:234-236.
 34. Ross G, Grabill J, McDevitt E. Chondral injury after meniscal repair with bioabsorbable arrows. *Arthroscopy* 2000;16:754-756.
 35. Lombardi JA. Second-look arthroscopy with removal of bioabsorbable tacks. *Am J Orthop* 2000;29:125-127.
 36. Song EK, Lee KB, Yoon TR. Aseptic synovitis after meniscal repair using the biodegradable Meniscus Arrow. *Arthroscopy* 2001;17:77-80.
 37. Seil R, Rupp S, Dienst M, Mueller B, Bonkhoff H, Kohn DM. Chondral lesions after arthroscopic meniscus repair using Meniscus Arrows. *Arthroscopy* 2000;16:E17 (available online at www.arthroscopyjournal.org).
 38. Miller MD, Kline AJ, Gonzales J, Beach WR. Pitfalls associated with FasT-Fix meniscal repair. *Arthroscopy* 2002;18:939-943.
 39. Schneider F, Schroeder JH, Labs K. Failed meniscus repair. *Arthroscopy* 2003;19:e8-e11 (available online at www.arthroscopyjournal.org).