

Arthroscopic Patella Realignment: An All-Inside Technique

Jeffrey L. Halbrecht, M.D.

Purpose: Many methods of realigning the patella have been described. Most techniques for proximal realignment involve an open medial reefing or advancement of the vastus medialis obliquus. Arthroscopically assisted methods have been described, but these all involve the need for a medial incision to tie sutures. This article describes an entirely arthroscopic technique for proximal realignment that eliminates the need for an incision, and reports the 2-year follow-up results using this technique. **Type of Study:** Retrospective review. **Methods:** Over a 5-year period, 26 patients (29 knees) with patellar instability were treated with an outpatient arthroscopic all-inside medial reefing and lateral release. Arthroscopic reefing was performed by percutaneous passage of suture followed by arthroscopic retrieval and knot tying inside the joint. Before knot tying, a healing response was initiated along the medial retinaculum by either gentle shaving with a whisker blade or by radiofrequency thermal response. Rehabilitation consisted of 1 week of immobilization followed by an accelerated program of range of motion exercises and vastus medialis obliquus strengthening. **Results:** At follow-up, 93% of patients reported significant subjective improvement. The average Lysholm score improved from 41.5 to 79.3 ($P < .05$). Preoperative and postoperative radiographs were measured for congruence angle, lateral patellofemoral angle, and lateral patella displacement, and all showed significant improvement postoperatively ($P < .05$). There were no complications and no redislocations. Patients reported a significant improvement in pain, swelling, stair climbing, crepitus, and ability to return to sports ($P < .05$). **Conclusions:** Arthroscopic patella realignment is a viable technique that offers results comparable or superior to published results for open or arthroscopically assisted realignment. **Key Words:** Patella dislocation—Patella realignment—Arthroscopic realignment—Medial reefing—All-inside technique.

Malalignment of the patella is a common problem. Most patients with this condition respond well to conservative treatment methods. Severe cases of malalignment can result in instability, including patella dislocation, and may require surgical intervention for correction.

For patients with patellar instability and normal bony anatomy, a proximal soft-tissue realignment is often recommended. Most reported techniques make use of a combination of lateral release and some open procedure to tighten the medial retinaculum,¹ advance the vastus medialis obliquus,^{2,3} or transfer tissue to

stabilize the medial structures.⁴ Several techniques for arthroscopically assisted techniques have been proposed,⁵⁻⁷ but these also involve a medial incision. To date, no truly all-arthroscopic technique has been published. The author reports his experience with a new, entirely arthroscopic technique for patella realignment.

METHODS

Only patients with patellar instability were included in this study: 41 patients (45 knees) with a history of patellar instability underwent surgery for arthroscopic realignment between 1994 and 1999; 26 patients (29 knees) were available for follow up. Of the 29 knees, 23 were actual dislocators and 6 were subluxators. This procedure was not performed for simple malalignment and those patients were not included in this study. The criteria for surgery were either recurrent dislocators/subluxators who had failed at least 6

From Private Practice, San Francisco, California, U.S.A.
Address correspondence and reprint requests to Jeffrey L. Halbrecht, M.D., 2100 Webster St, Suite 331, San Francisco, CA 94115, U.S.A. E-mail: J.Halbrecht@IASM.com
© 2001 by the Arthroscopy Association of North America
0749-8063/01/1709-2828\$35.00/0
doi:10.1053/jars.2001.28980

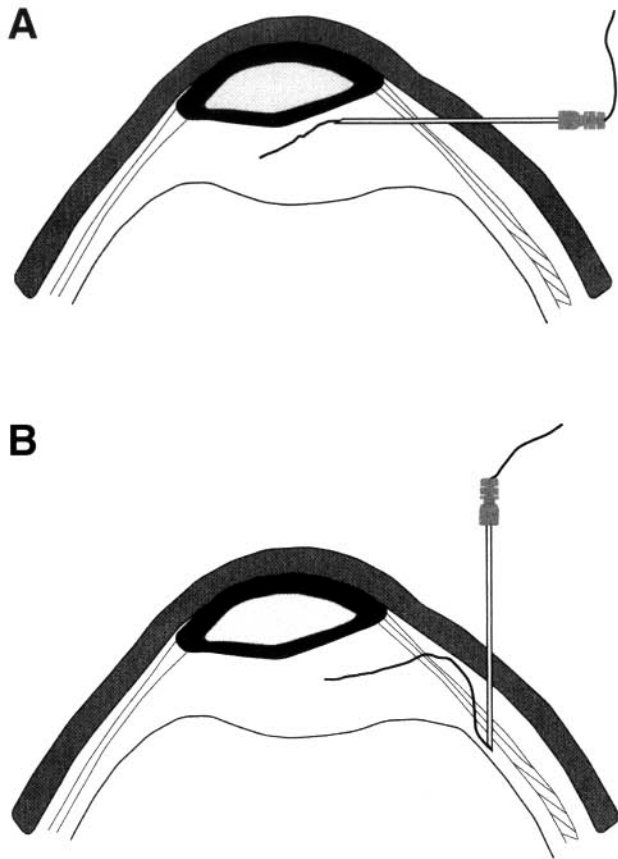


FIGURE 1. Technique for arthroscopic medial reefing. (A) No. 1 PDS suture is passed through a 17-gauge epidural needle that has been inserted percutaneously through the medial retinaculum. (B) The needle is withdrawn and reinserted through the retinaculum only, without withdrawing through the skin, thus creating an all-inside stitch.

months of conservative treatment, or acute dislocators who had significant residual lateral translation shown on their postreduction Merchant view radiograph. The average Q angle in this group was 11° and no patient had evidence of patella alta or trochlea hypoplasia.

For the purposes of this study and data analysis reported in this article, each knee is considered a separate subject. There were 15 male knees and 14 female knees. The right leg was involved in 11 patients, and the left leg in 18. The average patient age was 30 years (range, 17 to 50 years). Follow-up examination included physical, radiographs, Lysholm score, and a patella score administered by the author.

Surgical Technique

All patients underwent a patella realignment utilizing an all-inside arthroscopic technique. Surgery was

performed under general anesthesia with a thigh holder in place. A tourniquet was applied but was rarely inflated. Before plication, a healing response was created along the medial retinaculum by gently shaving with a whisker blade or, later in the study, by using a thermal radiofrequency technique (Oratec, Menlo Park, CA).

Medial retinacular sutures were introduced percutaneously using an epidural needle (Tuohy Needle; Rusch, Deluth, GA). An epidural needle is essential because of the noncutting edge on the inner bevel of the tip that prevents cutting of the suture. The needle is placed adjacent to the patella and a No. 1 PDS suture is passed manually through the needle and retrieved arthroscopically through an accessory superolateral portal (Fig 1). The needle is gently withdrawn from the retinaculum but not out of the skin. The needle is then redirected subcutaneously approximately 2 to 3 cm posteriorly and reinserted through the retinaculum again. This creates a loop of suture that is retrieved again through the same accessory portal. The needle is then withdrawn completely and the process repeated until 4 to 5 sutures are in place. The sutures are clamped for later imbrication of the medial retinaculum. An arthroscopic lateral release is then performed with a standard electrocautery device. After the lateral release, the medial sutures are retrieved individually via a cannula in the anteromedial portal (Fig 2) and tied inside the joint from either the anteromedial or proximal lateral portal using standard arthroscopic knot-tying techniques (Fig 3).

Postoperative treatment involved a brace locked in full extension for 1 week, followed by physical therapy for 2 to 3 months. After the first week, the brace was unlocked to enable patients to begin range of

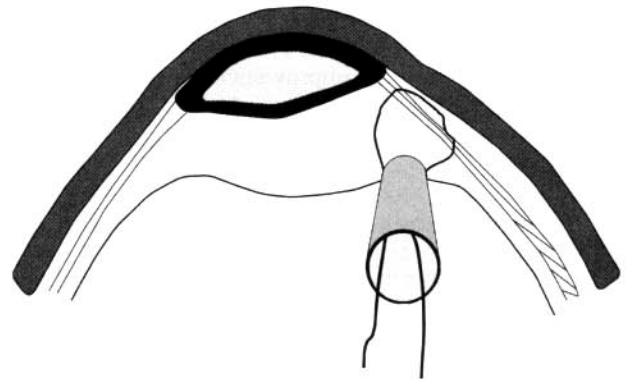


FIGURE 2. The suture ends are retrieved out the anteromedial portal and tied using standard arthroscopic knot-tying techniques.

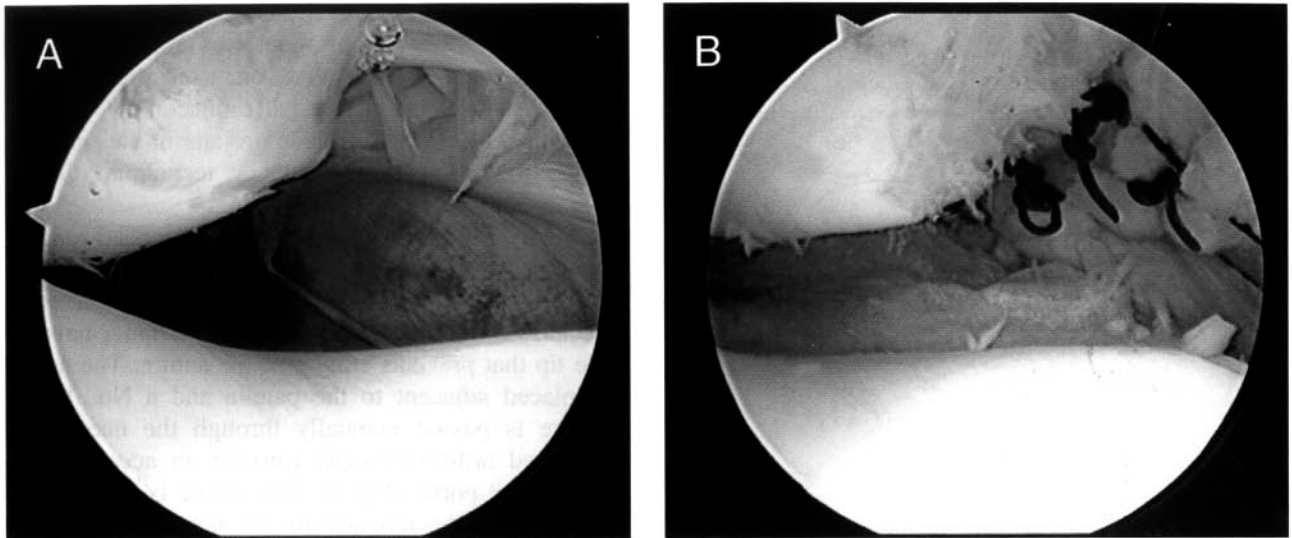


FIGURE 3. Arthroscopic appearance (A) before and (B) after all-inside patella realignment. Note the appearance of the sutures along the medial retinaculum tied from inside the joint.

motion exercises, but bracing was continued for 3 to 4 weeks until quadriceps strength returned. Patients were not allowed to flex past 90° for 4 weeks, but could begin weight bearing immediately in the brace. Follow-up time averaged 20 months.

RESULTS

Lysholm Score: The Lysholm score improved from 41.5 preoperatively to 79.3 postoperatively ($P < .05$).

Patient Satisfaction: When patients were asked to evaluate their results on a simple subjective rating scale, 27 (93%) felt that they were significantly better, 1 patient felt that she was worse, and 1 felt that there was no change ($P < .05$). Patients were evaluated on a subjective rating scale for pain, swelling, crepitus, and instability, with 10 considered the worst possible symptoms, and 0 as no symptoms (Table 1).

Patients reported an improvement in pain from 7.1 preoperatively to 2.4 postoperatively ($P < .05$). Crepitus improved from 6.6 preoperatively to 2.5 postoperatively

($P < .05$). Swelling improved from 6.0 to 0.8 ($P < .05$). Instability improved from 8.2 to 0.8 ($P < .05$).

Return to sports participation was rated on a reverse scale, with 10 being full return to sports and 0 being sedentary. Patients improved from an average preoperative score of 3.0 to 6.8 postoperatively ($P < .05$).

Range of Motion: All patients regained full range of motion postoperatively according to objective goniometric measurement. No patients required manipulation or repeat surgery.

Atrophy: Postoperative atrophy measured 0.9 cm at the most recent follow-up. Some patients were still in rehabilitation.

Patella Tracking: On physical examination postoperatively, all patients had a normal patellar tilt (neutral or greater), negative apprehension sign, and excellent stability in response to attempted manual translation of the patella (<50% lateral translation). None of the realigned patellae could be manually subluxated or dislocated. The average Q angle in these patients was 11.3° with a range of 8° to 16° .

Radiographic Evaluation: Radiographic evaluation using standard Merchant view radiographs before and after realignment was performed in 24 of the 26 patients. Preoperative and postoperative measurements were made for congruence angle, lateral patellofemoral angle, and lateral patellar translation. Films were also evaluated for evidence of degenerative arthritis, including osteophyte formation and narrowing of the patellofemoral joint.

TABLE 1. Subjective Rating: 10 (severe symptoms) to 0 (no symptoms)

	Preoperative	Postoperative	P Value
Pain	7.1	2.4	<.05
Swelling	6.0	0.8	<.05
Instability	8.2	0.8	<.05
Crepitus	6.6	2.5	<.05

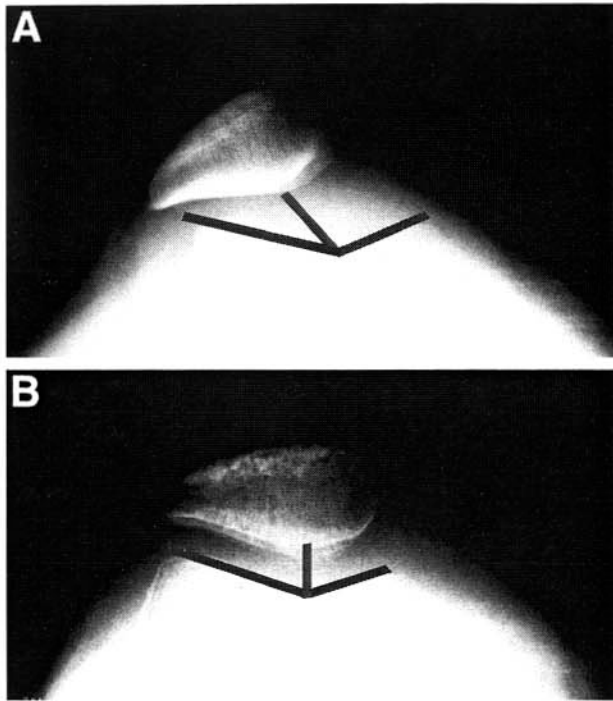


FIGURE 4. (A) Preoperative and (B) postoperative Merchant view radiographs showing improvement in the congruence angle. The average improvement in congruence angle was from 30.7° preoperatively to 8.2° postoperatively.

Congruence Angle: The congruence angle improved from an average of 30.7° preoperatively to 8.2° postoperatively ($P < .05$) (Fig 4).

Lateral Patellofemoral Angle: The lateral patellofemoral angle improved from an average of -3° preoperatively to $+9.4^\circ$ postoperatively ($P < .05$) (Fig 5).

Lateral Translation: Preoperative lateral translation improved from 8.0 mm to 1.2 mm following realignment ($P < .05$) (Fig 6).

Degenerative Changes: Six patients had evidence of early osteophyte formation or narrowing. Arthroscopic inspection revealed that 25 patients had either grade 3 (16 patients) or grade 4 (9 patients) chondromalacia.

DISCUSSION

Long-term results suggest that the natural history of nonoperative treatment of patellar instability is poor. In a group of 20 patients with acute dislocations treated conservatively, Hawkins et al.⁸ reported a 20% incidence of ongoing instability, and a 15% incidence of pain and crepitus. In their series of 48 patients with

acute dislocations, Cofield and Bryan⁹ reported a 44% incidence of redislocation; 27% of these patients went on to subsequent surgery and, taking into account subjective criteria, 52% were considered failures. In 21 patients treated nonoperatively, McManus et al.¹⁰ reported 5 redislocations and 11 patients who remained symptomatic. Cash and Hughston¹¹ reported a redislocation rate of 20% to 43% depending on anatomic evidence of dysplasia predisposing to instability.

Relative indications for surgical treatment of patellar instability include failure of conservative treatment, the presence of an osteochondral fracture (loose body) following a dislocation, and severe residual malalignment on a postreduction radiograph following dislocation.

Various surgical techniques have been proposed to correct patellar instability. Lateral release alone has been described, although results have been mixed, with a high incidence of recurring instability.¹²⁻¹⁴ Lateral release alone does not address the disrupted anat-

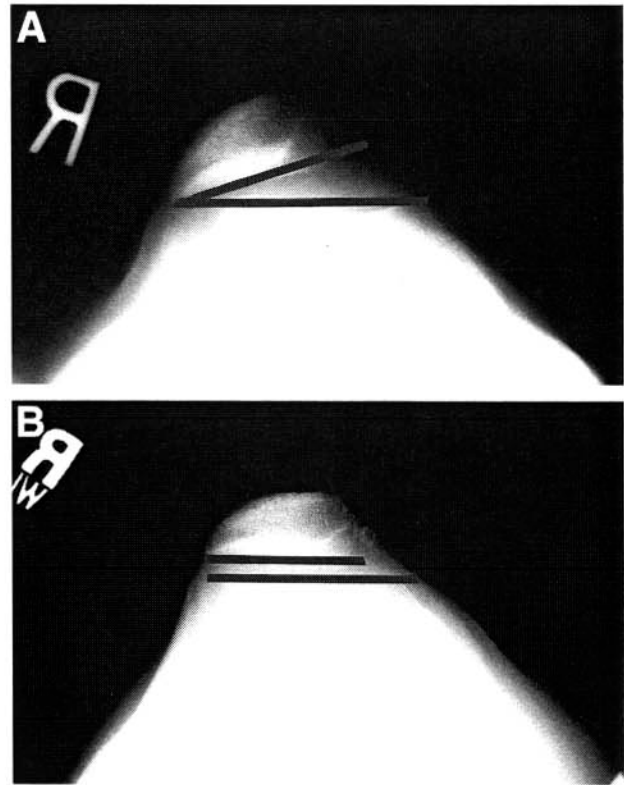


FIGURE 5. (A) Preoperative and (B) postoperative Merchant view radiographs showing improvement in lateral patellofemoral angle. The average improvement in the lateral patellofemoral angle was from -3° preoperatively to $+9.4^\circ$ postoperatively.

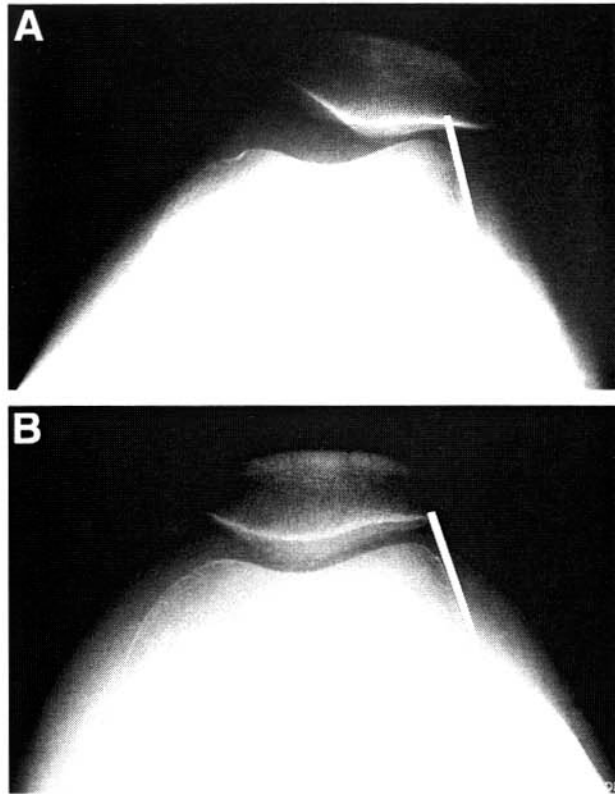


FIGURE 6. (A) Preoperative and (B) postoperative Merchant view radiographs showing improvement in lateral patellar translation. The average improvement in translation was from 8.0 mm preoperatively to 1.2 mm postoperatively.

omy of the medial retinaculum and is not considered by most authors to be an effective treatment for true patellar instability or malalignment.¹⁵ When surgery is indicated for patellar instability, most authors have recommended some sort of proximal soft-tissue realignment. Surgical recommendations have included the classic Roux-Goldthwait procedure of transferring the medial half of the patella tendon laterally,⁴ extensive open reefing as described by Insall et al.,² and minimally invasive open procedures for repair of the medial retinaculum.¹ Several arthroscopically assisted procedures have also been reported.⁵⁻⁷

For severe cases of patellar instability, reconstructive procedures to recreate the medial patellofemoral ligament have also been described, using the medial hamstrings or even synthetics.¹⁶ Distal bony realignment procedures are reserved for patients with severe cases of malalignment and a high Q angle¹⁵ or for patients who have failed previous proximal soft-tissue realignments.¹

Arthroscopic Realignment

Several methods for arthroscopic patella realignment have been proposed, but they have consisted primarily of arthroscopically assisted techniques using a medial incision. Yamamoto⁶ treated 30 acute patella dislocations with arthroscopic lateral release along with an arthroscopically assisted repair of the medial retinaculum. He recommended the transcutaneous passage of sutures through the retinaculum using a large curved needle, although the sutures were still tied through a medial skin incision. Only acute dislocations were treated. Reported results were excellent, with only one reported case of redislocation.

Small⁵ reported a modified version of the Yamamoto technique, also utilizing an arthroscopically assisted method and a small medial incision. Patients with acute and recurrent dislocations were included as well as patients with malalignment and subluxation. Results were good/excellent in 92.5% of their 24 patients (27 knees) according to a subjective questionnaire. There were 2 recurrent subluxations, 1 reoperation for arthrofibrosis, and 1 superficial infection.

Henry and Pflum⁷ described an arthroscopically assisted technique using cannulated needles, but tied the sutures through a medial incision as well. No follow-up series or results were reported.

Current Recommendations

Our initial procedure of choice for patients with patellar instability and normal bony anatomy is an arthroscopic proximal realignment as described in this article. The subjective and objective results have been outstanding, including excellent stability, and there have been no reported complications. Although open realignment procedures can also be effective in preventing recurring instability, these procedures are frequently accompanied by the risk of joint stiffness and scar tissue. None of our patients required a second operation for debridement of scar tissue or manipulation. All patients regained full range of motion as compared with the opposite side. We believe that this procedure is also preferable to previously described arthroscopically assisted methods, in that an incision is avoided and the vastus medialis obliquus is not violated.

CONCLUSION

Realignment of the patella can be performed as an arthroscopic all-inside technique with overall excellent results. This method eliminates the need for an

incision and produces results comparable if not superior to those previously reported for open and arthroscopically assisted techniques.

REFERENCES

1. Aglietti P, Buzzzi NR, Insall JN. Disorders of the patellofemoral joint. In: Insall JN, ed. *Surgery of the knee*. Ed 1. New York: Churchill Livingstone, 1993;241-385.
2. Insall JN, Bullough PG, Burstein AH. Proximal tube realignment of the patella for chondromalacia patellae. *Clin Orthop* 1979;144:63.
3. Insall JN. Disorders of the patella. In: Insall JN, ed. *Surgery of the knee*. Ed 2. New York: Churchill Livingstone, 1984;191.
4. Fondren FB, Goldner JL, Bassett FH. Recurrent dislocation of the patella treated by the modified Roux-Goldthwait procedure: A prospective study of forty-seven knees. *J Bone Joint Surg Am* 1985;67:993.
5. Small NC. Arthroscopically assisted proximal extensor mechanism realignment of the knee. *Arthroscopy* 1993;9:63-67.
6. Yamamoto RK. Arthroscopic repair of the medial retinaculum and capsule in acute patellar dislocations. *Arthroscopy* 1986;2:125-131.
7. Henry JE, Pflum FA Jr. Arthroscopic proximal patella realignment and stabilization. *Arthroscopy* 1995;11:424-425.
8. Hawkins RJ, Bell RH, Anisette G. Acute patella dislocations: The natural history. *Am J Sports Med* 1986;14:117.
9. Cofield RH, Bryan RS. Acute dislocation of the patella: Results of conservative treatment. *J Trauma* 1977;17:526.
10. McMannus MB, Rang M, Heslin J. Acute dislocation of the patella in children. *Clin Orthop* 1979;139:88.
11. Cash JD, Hughston JC. Treatment of acute patella dislocation. *Am J Sports Med* 1988;16:244.
12. Aglietti P, Pisaneschi A, De Biase P. Lussazione recidivante di rotula: Tre tipi di trattamento chirurgico. *G Ital Ortop Traumat* 1992;13:25.
13. Dandy DJ, Griffiths D. Lateral release for recurrent dislocation of the patella. *J Bone Joint Surg Br* 1989;71:121.
14. Sherman OH, Fox JM, Sperling H, et al. Patellar instability: Treatment by arthroscopic electrosurgical lateral release. *Arthroscopy* 1987;3:152.
15. Fulkerson JP, Cautilli RA. Chronic patella instability: Subluxation and dislocation. In: Fox JM, Del Pizzo W, eds. *The patellofemoral joint*. New York: McGraw-Hill, 1993;135-147.
16. Baker R, Carroll N, Dewar P, Haugh J. Semitendinosis tenodesis for recurrent dislocation of the patella. *J Bone Joint Surg Br* 1972;54:103.